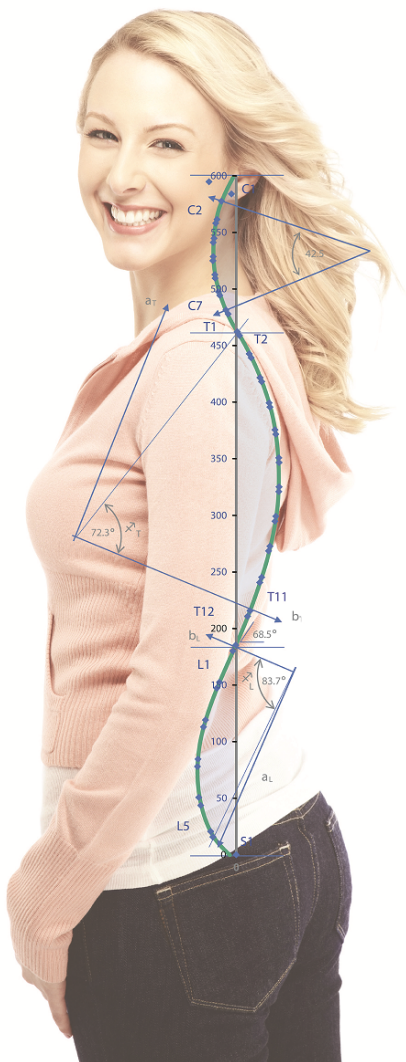




MODERN CHIROPRACTIC CENTER

X-RAY Report of Findings



Prepared for : Bad Spine

Evaluation Date : 6/29/2013

Date X-Ray Taken: 6/29/2013

Prepared by:
Modern Chiropractic
Someplace Drive
Somewhere Cityville, Florida
34653



Welcome

You have chosen to be a patient at an office that utilizes posture and x-ray to evaluate your spinal alignment. While a postural analysis can provide a knowledge of gross postural/spinal abnormalities (your outside alignment), only a radiographic evaluation can provide the details of your spine's alignment and condition (your inside alignment). Your spinal alignment, any possible spinal arthritis, and disc disease (S.A.D.D.) are both conditions of interest to your doctor. With the knowledge from analyzing your spinal x-rays, your health care provider can determine a beginning clinical impression (diagnosis from any abnormalities found on your x-rays) and determine an initial program of corrective care.

What is Normal for the Spine?

Your doctor performs several levels of analyses on your spinal x-rays. First, an overall evaluation of your alignment in front-to-back radiographic views and your side radiographic views is performed. In the Front view, your spine should be straight or vertically aligned with gravity. In the Side view, your spine should have four natural curves. These four curves should be a convex forward curve in the neck (termed lordosis), a concave curve in the rib cage area (termed thoracic kyphosis), another convex forward curve in the low back (termed lumbar lordosis), and a concave curve in your sacrum-tailbone area. Figure 1 illustrates this alignment.

Figure 1.

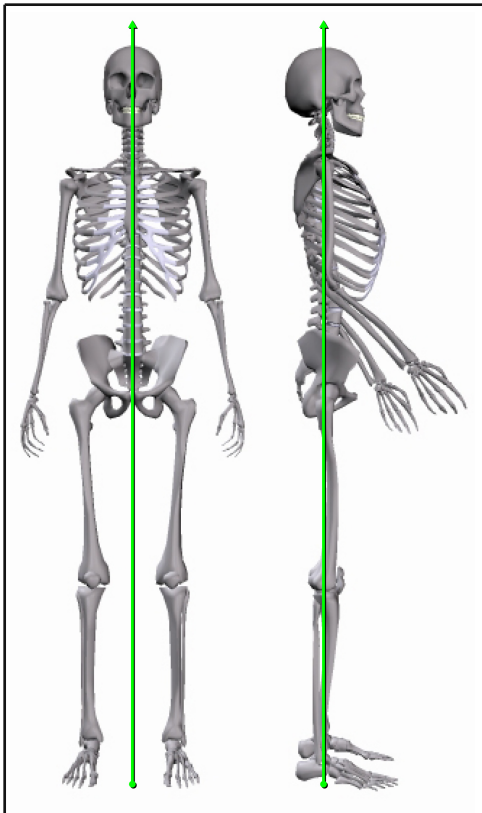


Figure 1.

Normal spinal alignment is depicted in both the front and Side views. In the front view, the center of mass of the skull, thorax, and pelvis are in a vertical line which falls between mid-stance. The spinal column is vertically aligned with respect to gravity. In the side view, the center of mass of the skull, thorax, and pelvis are in vertical alignment over the ankle. The cervical spine is lordotic, the thoracic spine is kyphotic, and the lumbar spine is lordotic.



X-RAY Report of Findings

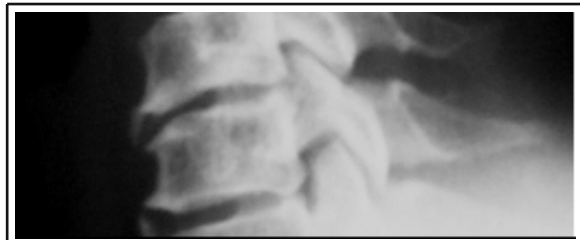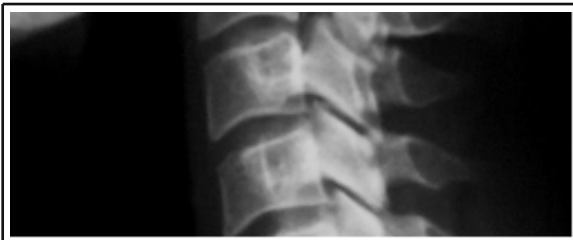Introduction

For a second evaluation, your doctor looks for any obvious spinal ligament damage by observing individual spinal vertebra for any left or right misalignments in the front view and any forward or backward misalignments in the side view. Figure 2 illustrates cases of spinal ligament damage.




Figure 2. Ligament damage is present when a spinal vertebra does not align properly with either the vertebra immediately above it or immediately below it. In the 1st and 2nd picture, abnormal alignment of a vertebra translating left and right, signifying spinal ligament damage, is illustrated for the front view. In the 3rd picture, in the side view, backward slippage of the top vertebra is depicted. In the 4th picture, in the side view, forward slippage is shown.

For a third evaluation of your spinal x-rays, your doctor checks each vertebra for normal contour and density. This evaluation determines the state of any possible spinal arthritis and disc disease (S.A.D.D.) that you may have. Figure 3 provides an example of this analysis.



For a fourth evaluation of your spinal x-rays, your doctor checks the spacing between each pair of vertebrae. This spacing is where the spinal discs lie. Any narrowing of the normal spacing indicates disc injury and disc disease. Figure 4 presents an example of disc narrowing and disease.

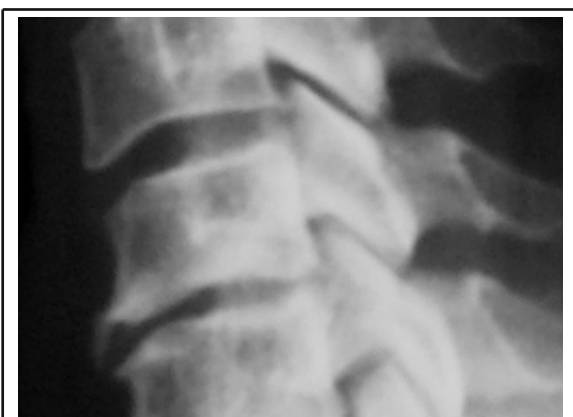

Figure 4. Between the top and middle vertebrae, a normal disc spacing is seen. However, between the middle and lower vertebrae, the disc space is narrowed. This indicates that the disc has been injured and is losing its water content. While disc disease can have several causes, generally, it is a result of abnormal stress (pressures) applied to the disc from abnormal spinal alignment.



X-RAY Report of Findings

Introduction

For a fifth evaluation of your spinal x-rays, your doctor determines the alignment of each spinal region (neck, rib cage, and low back) compared to the region immediately below by comparing each region to a vertical line in both the front view and side view. The following vertebrae should be vertically aligned with each other: C1 (first neck vertebra), T1 (first rib cage vertebra), T12 (last rib cage vertebra at the level of your kidneys), and S1 (first vertebra in your sacrum). Figure 5 illustrates this alignment for the three separate spinal regions, neck, rib cage, and low back.

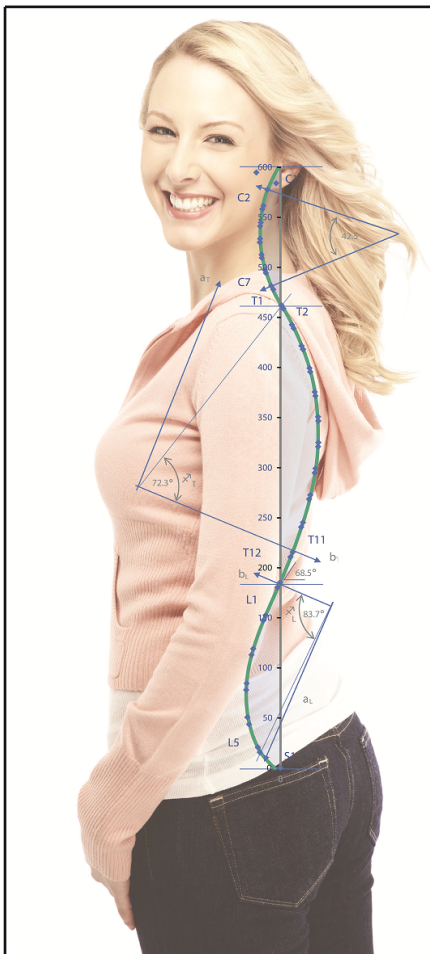


Figure 5.

Normal spinal balance from the side is when a vertical line will pass through C1, T1, T12, and S1. This can be observed all at once on a full-spine side view x-ray or for individual regions on smaller x-ray views, termed sectional x-rays. The figure to the left shows only the posterior points of each vertebra. If we look at the side view cervical (neck), C1 is aligned with T1 (thick vertical black line), with a forward convex curve termed cervical lordosis. If we just look at the side view of rib cage (thoracic), T1 is aligned with T12 and there is the presence of a concave curvature (termed thoracic kyphosis). If we look at the side view lumbar (low back), T12 is aligned with S1, with a forward convex curve termed lumbar lordosis.

For a sixth evaluation, your doctor measures any displacements of the individual spinal vertebra and/or spinal regions. These measurements are in degrees for any angular or turning (rotational) displacements and in millimeters for any sliding or shifting (translational) displacements. Figures 6 and 7 illustrate these measurements.



X-RAY Report of Findings

Introduction

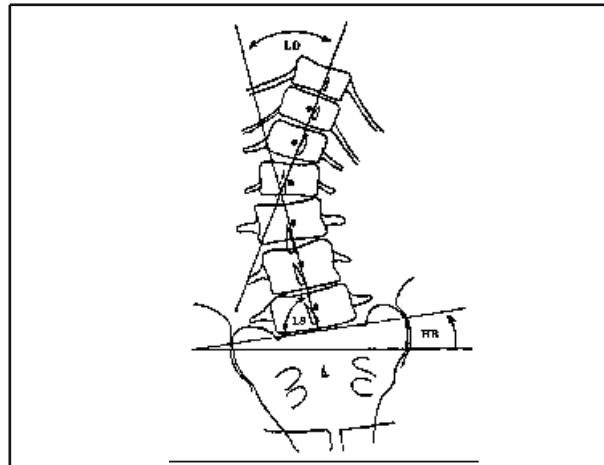
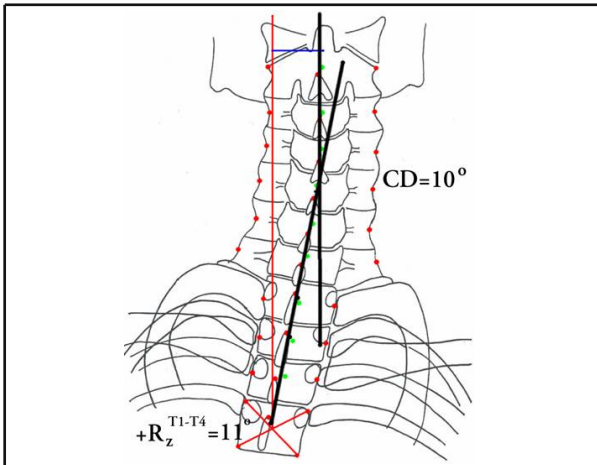


Figure 6. In the front x-ray views, lines are drawn through the centers of mass of each spinal vertebra to measure your abnormal spinal alignment. In A, an example of an analysis of abnormal spinal alignment of the neck in the front view is provided, and in B, an example of an analysis of abnormal spinal alignment of the low back is shown.

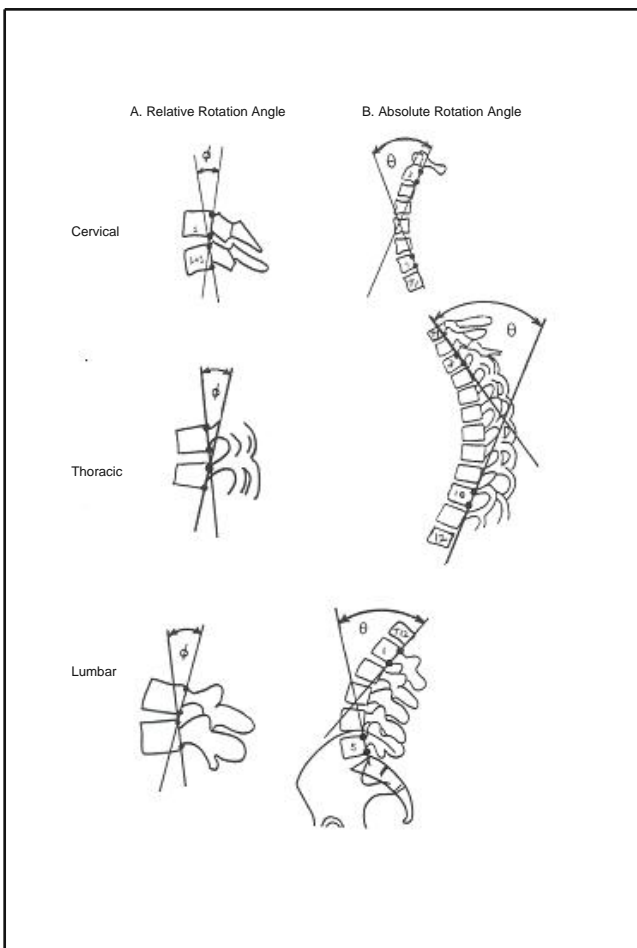


Figure 7.

In the side view, lines are drawn on the back part of each spinal vertebra. These lines are termed “Posterior Tangents”. When measuring angles between adjacent posterior tangents, the angles are termed Relative Rotation Angles (RRA). When angles are formed by posterior tangents on the top and bottom vertebrae in any spinal region, these angles are termed Absolute Rotation Angles (ARA). There are precise normal values published in the scientific literature for each spinal RRA and each spinal ARA. Your alignment will be compared to these published normal values.



What Are the Risks of X-ray Exposure?

While we must constantly work towards the reduction of health risks in all endeavors, we may be led to accept a minimal level as normal. While there is no data indicating diagnostic radiology has a present risk, any radiation dose must be compared to the benefits of useful information gained. The necessity for appropriate treatment selection is indeed an acceptable trade-off when put into perspective. The need for x-ray imaging is especially clear when one considers that radiographic (x-ray) imaging is the only valid method for determining abnormal spinal alignment and the presence of any spinal degeneration. However, since 1990, there has been a growing knowledge base that suggests medical x-rays may have health benefits. While an actual benefit from radiation exposure may seem outrageous, there is much scientific evidence for this phenomenon. This phenomenon/field of study is termed Radiation Hormesis.^[12-27,29-48]

Radiation Hormesis is the stimulatory or beneficial effect of low doses of ionizing radiation. This topic is in direct conflict with the "Linear No-Threshold Hypothesis" (LNT), which has been assumed to be true for more than 50 years. This LNT model comes from estimating the risks at lower doses of radiation, in the absence of data, by extrapolating in a linear model from the extremely large doses of radiation from atomic bombs dropped on Japan in the 1940s.

This LNT model has been used to set limits of radiation exposure by all official and governmental associations around the world.^[17] Recently in 2003, Kauffman¹² reiterated that authors critical of exposure from diagnostic radiation always use the LNT model. This use of the LNT model includes the recent 2005 report by the USA National Research Council.^[28] This report stated, "there will be some risk, even at low doses (100 mSv or less), although the risk is small" and "there is no direct evidence of increased risk of non-cancer diseases at low doses."^[28] This 2005 report ignored and contradicted an earlier 2003 review by Kant et al.^[29]

For a comparison of exposures, USA citizens are exposed to an average annual natural background radiation level of 3 mSv, while exposure from a chest x-ray is approximately 0.1 mSv and exposure from a whole body computerized tomography (CT) scan is approximately 10 mSv.^[28] Also it is noted that 10mSv = 1,000mrem, which equates to about 46 cervical series or 8 lumbar series. Thus, the x-ray views taken to evaluate your spine in this office constitute a very small exposure compared to a CT scan or even annual background radiation from your natural environment.

Thus, it is obvious that the extremely small health risks (and maybe even some health benefits), associated with the x-ray exposure, needed to determine the state of health of your spine in this Report, are small indeed compared to the knowledge gained from this information.

From your radiographic examination at our office, we have determined the state of degeneration of your spine, and have determined the exact displacements of your spine. This knowledge not only gives us a working Clinical Impression/diagnosis of your spinal condition, but also determines the type of treatment that is needed to improve your spinal health condition.

We hope that you appreciate our thoroughness in examining and diagnosing your spinal health problems. In the next few pages, for each x-ray view obtained, we will present a normal view on the left hand side to compare to your x-ray on the right hand side. A table of values of normal measurements and your abnormal alignment will be provided on a Summary page after the x-ray photographs.



This Analysis Has Been Researched

We are proud to state that the normal spinal alignment presented in this report is the result of many research projects on spinal alignment in normal subjects.^[1-6] Normal values for all spinal angles and distances, utilized in this report, have been reported in the most prestigious journals in the Index Medicus literature.^[1-6] Your abnormal spinal displacements (subluxations) will be compared to these normals.

These measurements of spinal displacements, utilized here, are mathematical utilizing geometric methods. This geometric line drawing analysis has been shown to be very reliable (repeatable) and valid (accurate).^[7-11]

Clinical Impression/Diagnosis

A Clinical Impression (Diagnosis) of your condition is derived from a variety of sources, including the consultation and discussion of your health history with your doctor, any orthopedic and/or neurological examinations, range of motion examination, postural examination, and the radiographic examination.

For recordkeeping purposes, the Clinical Impression is reduced to numerical codes, which have been agreed upon world wide. These International Classification of Diseases codes are termed "ICD" codes, are given to healthcare providers in code books, and are lists of specific agreed upon numbers followed by brief descriptions. These numbered ICD codes make for easy communication of your health problems, when given to any third party payers or state government entities, i.e., insurance companies, Workers Compensation, lawyers, courts, State Boards, etc.

Generally, a patient can trace his/her present condition back to a past injury, which is termed mode of onset. Using ICD codes, your doctor has reduced your condition to 5 different categories: (1) mode of onset of condition (accidents, falls, etc), (2) global postural displacements, (3) regional and/or segmental spinal displacements, (4) unchangeable complicating factors (ligament damage, spinal fractures, osteoarthritis, etc), and (5) disease syndromes (headaches, neck pain, arm pain, mid back pain, low back pain, leg pain, sciatica, etc.).



X-RAY Report of Findings

Side View of Your Neck (Lateral Cervical View)

The normal healthy curvature of a neck from the side.

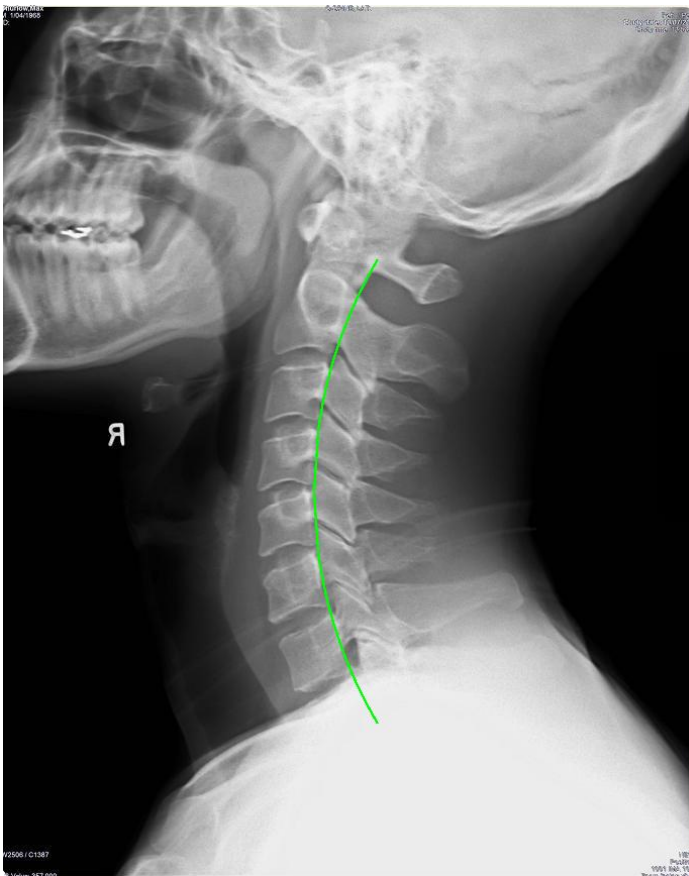
The green curved line represents the normal, healthy position for your neck.

No spinal arthritis is apparent and healthy disc spaces are visualized.

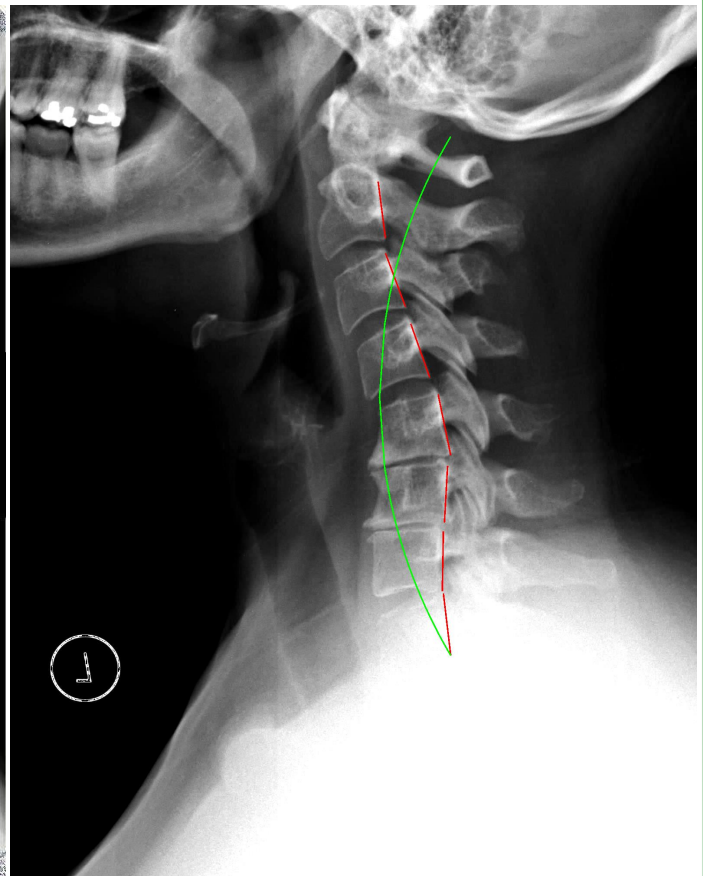
Your neck position from the side.

This green line represents the normal, healthy position for your neck.

This red line represents where your neck is currently positioned.



Front



Back Front

Back

Notes about your condition:

Your head is positioned 17.8 mm forward. Your neck curve measures 8.5° and should be -42.0° (a negative sign indicates lordosis or normal curve direction). This represents a 120.2% reduction in your curve compared to the normal neck curve.

This type of abnormal neck curve is usually caused from a traumatic event. This position is predictive of chronic neck and upper back pain statistically. The good news is our unique rehab methods have been shown effective for improving this abnormal position.

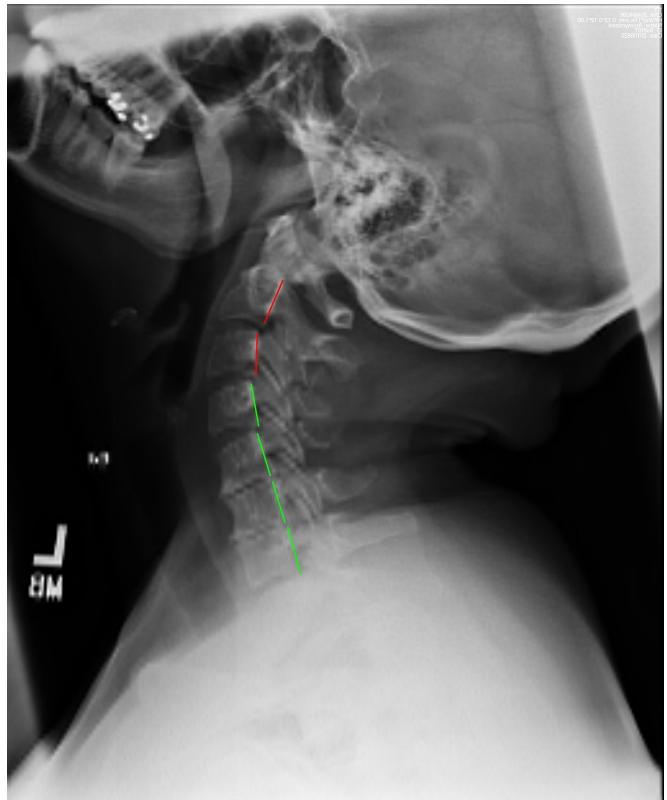
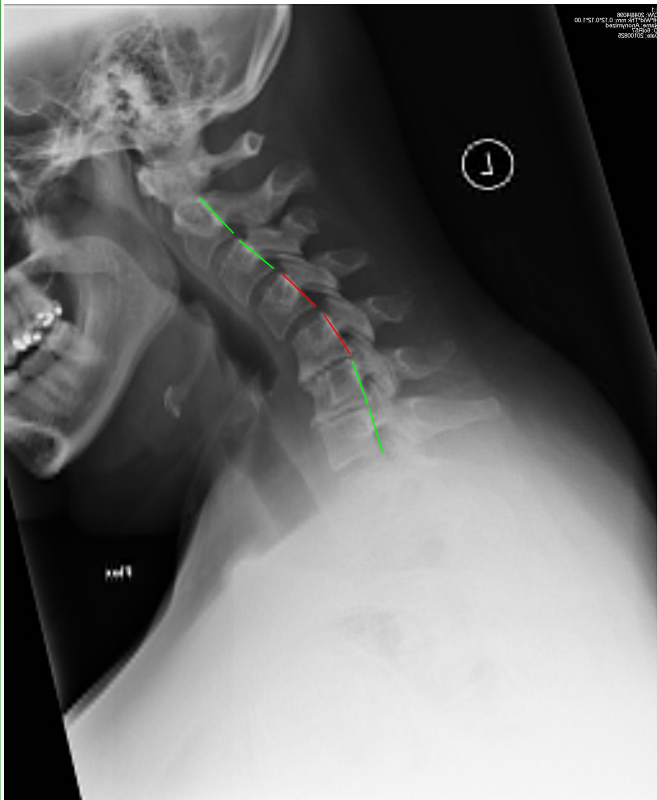

X-RAY Report of Findings

Side View of Your Neck Flexed and Extended (Lateral Cervical Flexion and Extension View)

This line represents where your neck is currently positioned with normal displacements.

This line represents where your neck is currently positioned with abnormal displacements.



Notes about your condition:

This x-ray is taken to observe the stability of your spinal ligaments when you bend your head forward and backwards. Ideally there should be minimal shifting of one vertebrae relative to the adjacent vertebrae. When spines are injured, it is common to see an abnormal increase in displacement slippage forward or backwards and/or an increase in angulation between

In your spine when you tip your head down (flexion position), you show possible damage at the C4-C5, C5-C6 spinal levels.

Ligamentous damage such as you demonstrate here is usually related to a traumatic event.

In the head backwards position (extension position), your spine demonstrates possible ligament damage at the C2-C3, C3-C4 spinal levels.



X-RAY Report of Findings

Front View of Your Upper Neck (AP Open Mouth View)

The normal healthy position of the neck from the front.

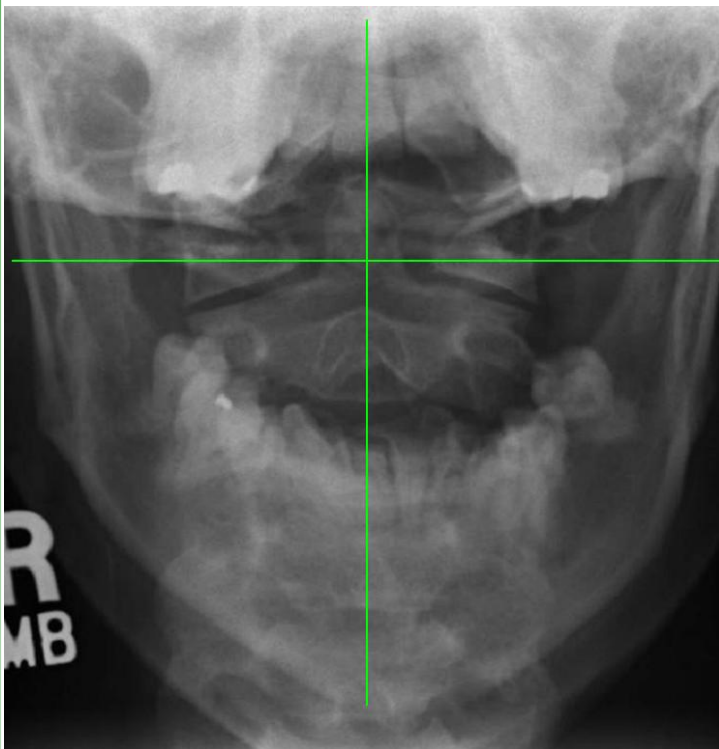
The horizontal line represents the normal atlas position. The vertical line is a plumb line, also indicating normal vertical spinal alignment.

No arthritis is apparent and healthy joint spaces are visualized.

Your neck position from the front.

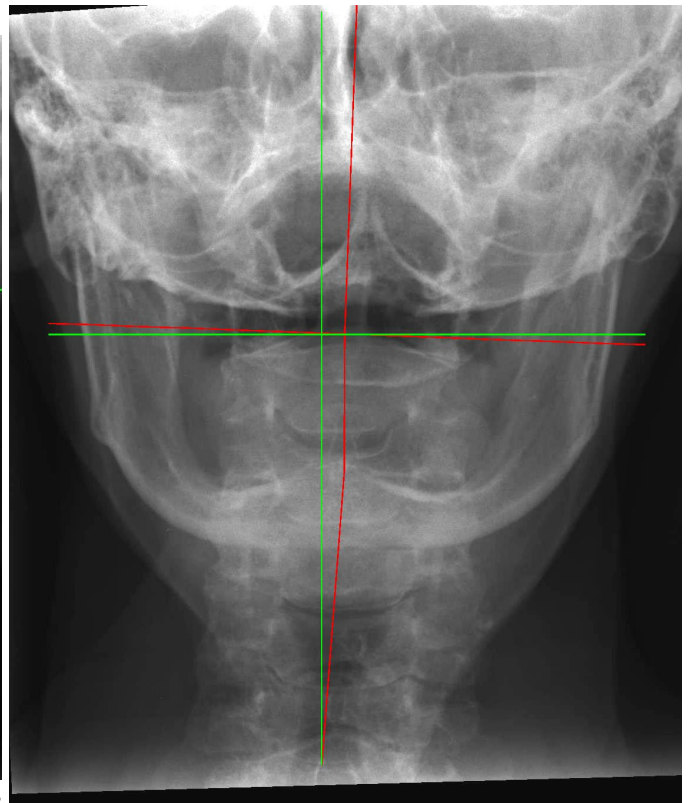
The green line indicates the normal position for your spine.

The red line indicates the abnormal current position for your spine.



Right

Left



Right

Left

Notes about your condition:

This x-ray is taken to mainly observe your upper neck position, the Atlas C1 Vertebrae) and Axis (C2 Vertebrae). Ideally the Atlas should rest upon Axis in a perfect vertical and horizontal alignment as viewed on the normal x-ray example. Your spine demonstrates that the left side of your Atlas is shifted 1.1 mm left off of the Axis (C2), and on the right side is shifted 1.5 mm to the left of the Axis.

Your Atlas known as C1 is the most important area of your spine. This abnormal alignment can contribute to symptoms you display.



X-RAY Report of Findings

Front View of Your Neck (AP Cervical View)

The normal healthy position of the neck from the front.

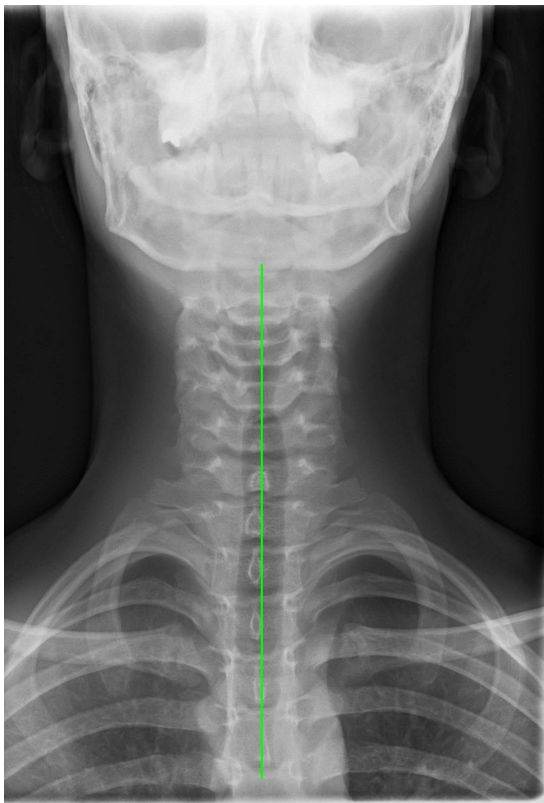
The green line represents the normal, healthy position for your neck.

No arthritis and healthy joint spaces are visualized.

Your neck position from the front.

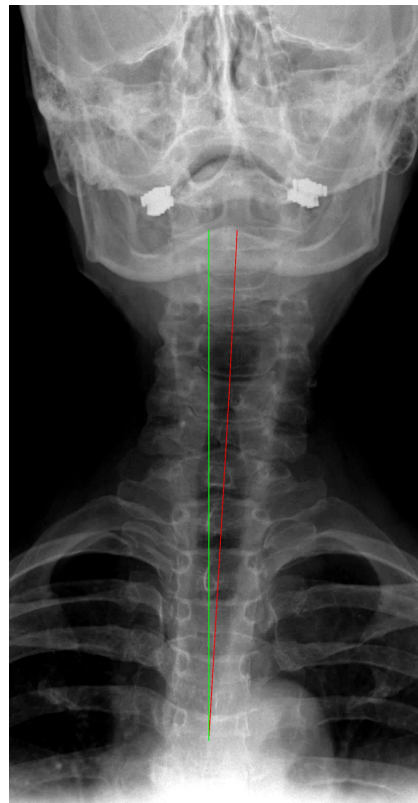
This green line represents the normal, healthy position for your neck.

This red line represents where your neck is currently positioned.



Right

Left



Right

Left

Notes about your condition:

Your head is shifted 9.8 mm to the left, you have a mid neck tilt angle of 0.8° to the right and a lower neck tilt of 3.3° to the left.

Your spine is shifted from plumb which has been linked to chronic neck pain.



X-RAY Report of Findings

Front View of Your Cervical/Thoracic (AP Nasium)

The normal healthy position of the neck from the front.

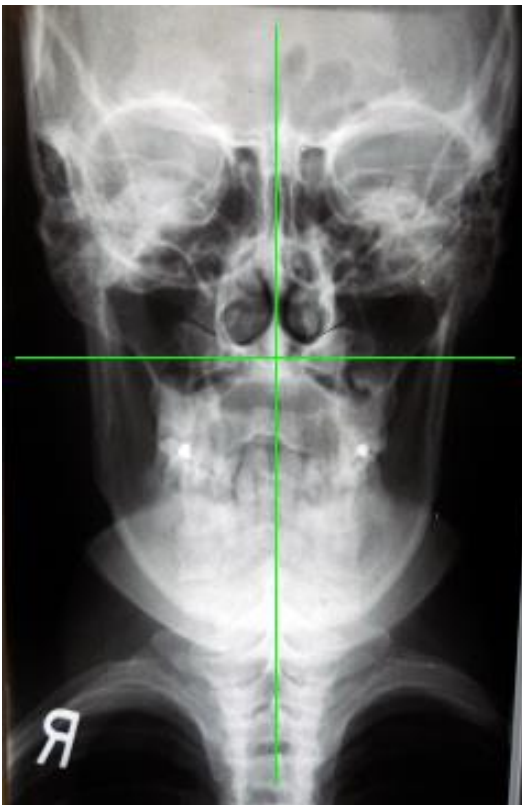The horizontal line represents the normal atlas position. The vertical line is a plumb line, also indicating normal vertical spinal alignment.

No arthritis is apparent and healthy joint spaces are visualized.

Your neck position from the front.

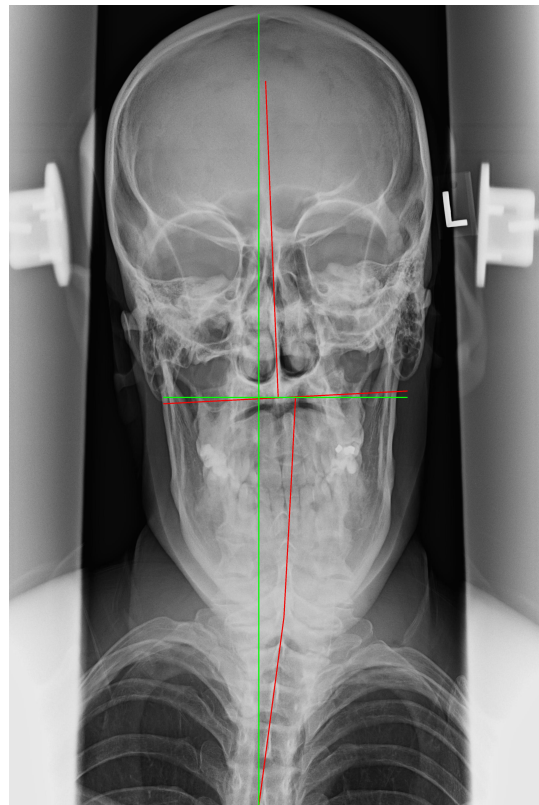
The green line indicates the normal position for your spine.

The red line indicates the abnormal current position for your spine.



Right

Left



Right

Left

Notes about your condition:

This neck x-ray is a specific for doctors to evaluate the integrity of your upper neck. When misalignments in this region occur, the effects can be full body. Doctors use angles to measure the alignment of this region. An offset of 0 degrees (90 degrees) is considered plumb and ideal. Your spine demonstrates that the left side of your Atlas is shifted 1.2 mm left off of the Axis (C2), and on the right side is shifted 1.7 mm to the left of the Axis.

Concerning the angular findings of atlas relative to the skull, your spine denotes an upper angle measurement of 0.7 degrees to the left and a lower angle of 6.1 degrees to the right. Ideal alignment in this region of the upper cervical region should approximate 0 degrees of offset of the upper angle and lower angle - meaning the skull sits perpendicular to the Atlas bone. The spine is translated (listed) from plumb by 14.6 mm to the left. Of importance, is that your spine has a mid neck cervico-dorsal angle of 6.6 degrees to the right.

Your spine is deviated from normal and contributes to your symptoms. The good news is that our rehab methods have been shown effective in cases such as yours.



X-RAY Report of Findings

Side View of Your Mid Back (Lateral Thoracic Spine)

**The normal healthy position of
a mid back from the side.**

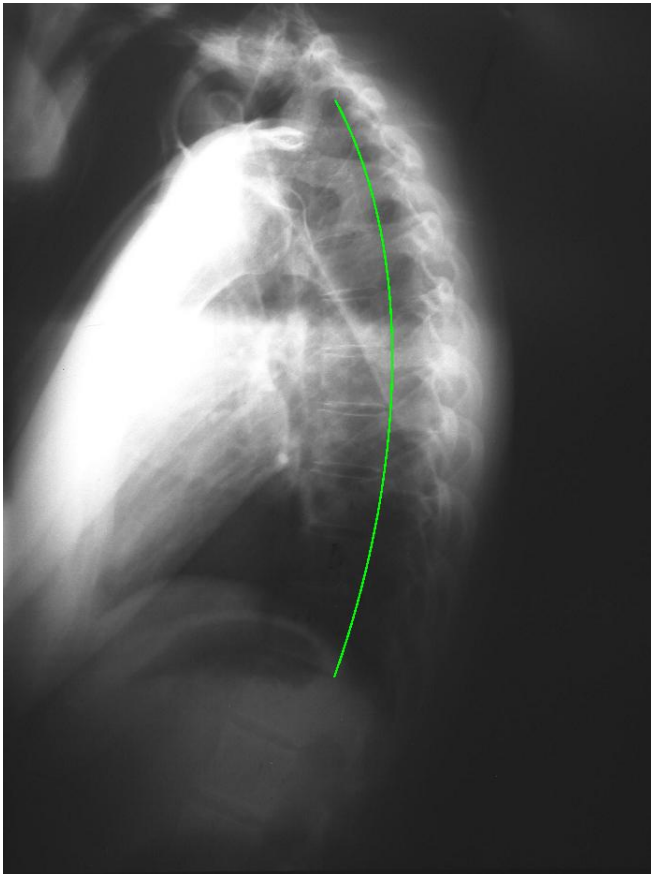
The green curved line represents the normal, healthy position for your ribcage.

No spinal arthritis is apparent and healthy disc spaces are visualized.

**Your mid back position
from the side.**

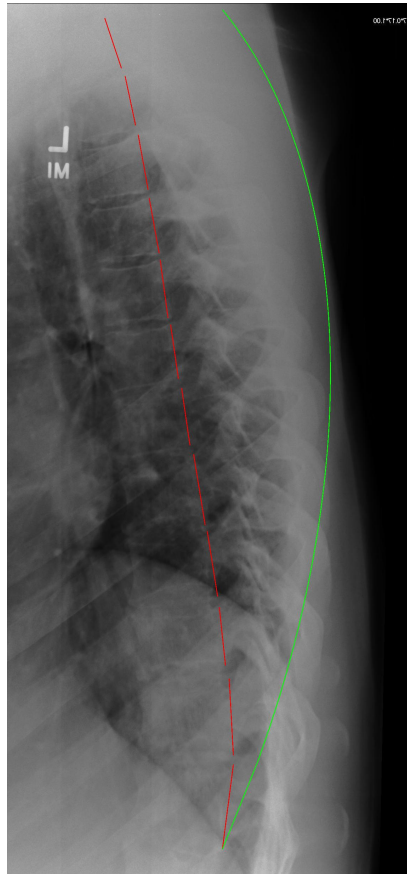
This green line represents the normal, healthy position for your mid back curve .

This red line represents where your mid back curve is currently positioned.



Front

Back



Front

Back

Notes about your condition:

Your spinal curve is positioned 49.0 mm forward. Your thoracic spine curve measures 25.8° and should be 44° . This represents a 41.3% decrease in your curve compared to the normal thoracic spine curve.

This abnormal spinal position can cause increased pain and accelerated degenerative changes in your spine.



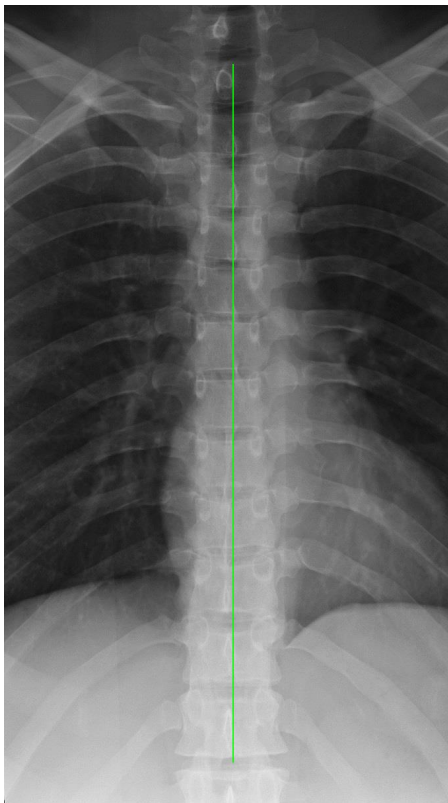
X-RAY Report of Findings

Front View of Your Thoracic

The normal healthy position of a mid back from the front.

The green line represents the normal, healthy position for your ribcage.

No arthritis and healthy joint spaces are visualized.



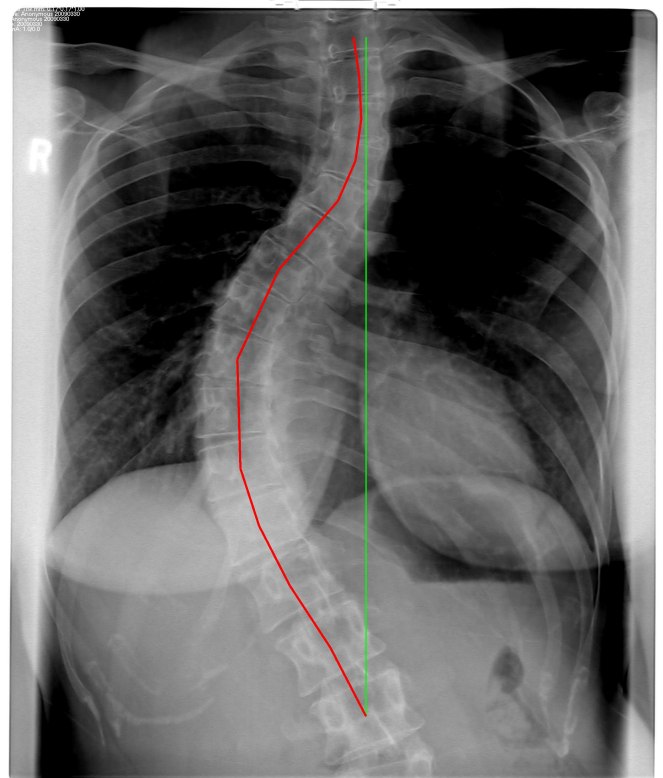
Right

Left

Your mid back position from the front.

This green line represents the normal, healthy position for your Thoracic spine.

This red line represents where your Thoracic spine is positioned.



Right

Left

Notes about your condition:

Your thoracic x-ray demonstrated that you have a scoliosis that consists of one major curvature. Your curve measured from vertebra T7 to vertebra T11 measured 47.2° (severe) using the "Cobb" method analysis and measured 26.5° (severe) using the "Risser-Ferguson" method of analysis. These methods of analysis are what spine doctors use to measure the severity of a scoliosis.

You have a significant scoliosis which I believe will stabilize and possibly reduce using our rehab methods along with a Scolicare brace as we discussed.



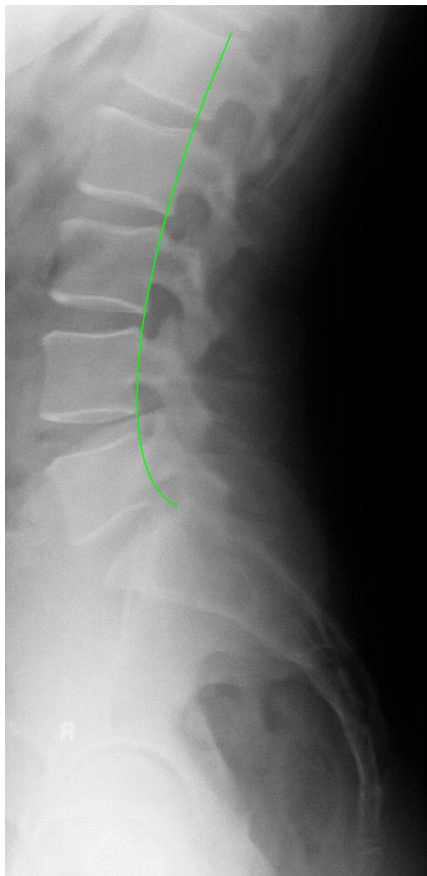
X-RAY Report of Findings

Side View of Your Low Back (Lateral Lumbar View)

The normal healthy curvature of a low back from the side.

The green curved line represents the normal, healthy position for low back curve.

No spinal arthritis is apparent and healthy disc spaces are visualized.



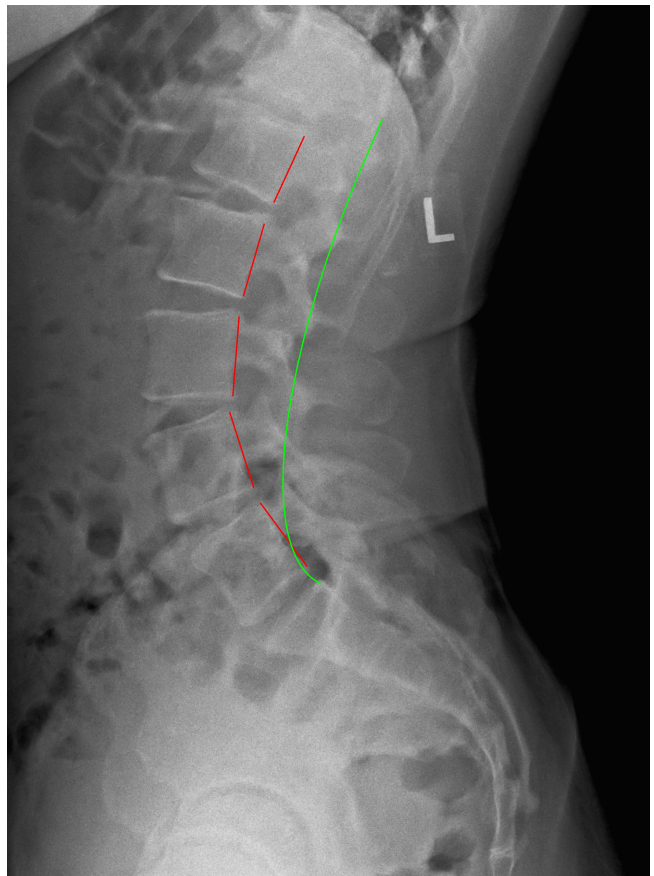
Front

Back

Your low back position from the side.

This green line represents the normal, healthy position for your low back curve.

This red line represents where your low back curve is currently positioned.



Front

Back

Notes about your condition:

Your rib cage is positioned 25.9 mm forward relative to your pelvis. Your low back curve measures -61.1° and should be -40° (a negative sign indicates lordosis or normal curve direction). This represents a 52.8% increase in your curve compared to the normal low back curve.

Your loss and abnormal position of your spine is linked to low back pain but can be improved through our unique rehab methods. Left uncorrected will ruin your Golf game.

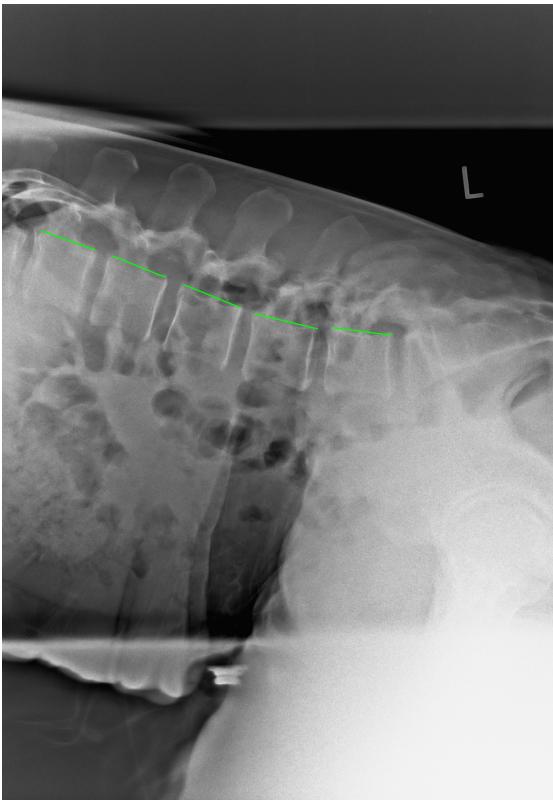


X-RAY Report of Findings

Side View of Your Low Back Flexed and Extended (Lateral Lumbar Flexion and Extension View)

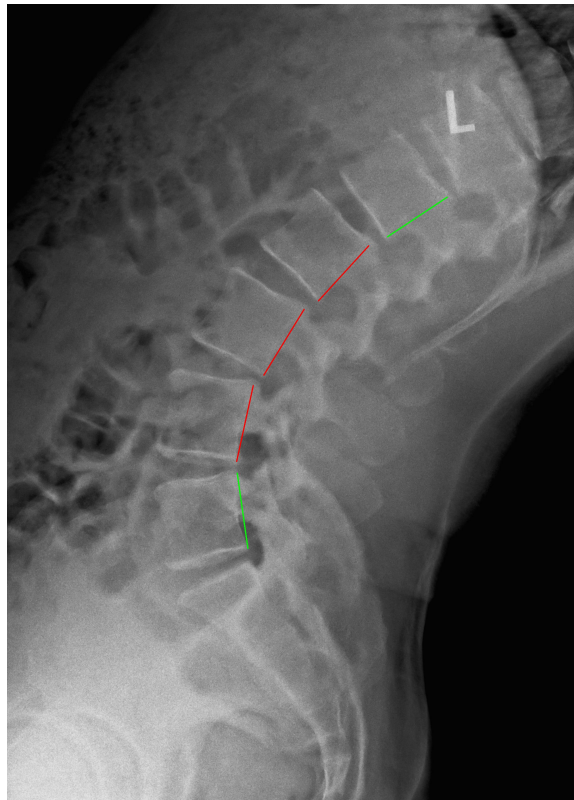
This line represents where your low back is currently positioned with normal displacements.

This line represents where your low back is currently positioned with abnormal displacements.



Front

Back



Front

Back

Notes about your condition:

This x-ray is taken to observe the stability of your spinal ligaments when you bend your rib cage forward and backwards. Ideally there should be minimal shifting of one vertebrae relative to the adjacent vertebrae. When spines are injured, it is common to see an abnormal increase in displacement slippage forward or backwards and/or an increase in angulation

In your spine when you tip your rib cage down (flexion position), you show possible damage at the T12-L1 spinal levels.

In the rib cage backwards position (extension position), your spine demonstrates possible ligament damage at the T12-L1, L2-L3, L3-L4, L4-L5 spinal levels.



X-RAY Report of Findings

Front View of Your Low Back (AP Lumbar View)

The normal healthy position of a low back from the front.

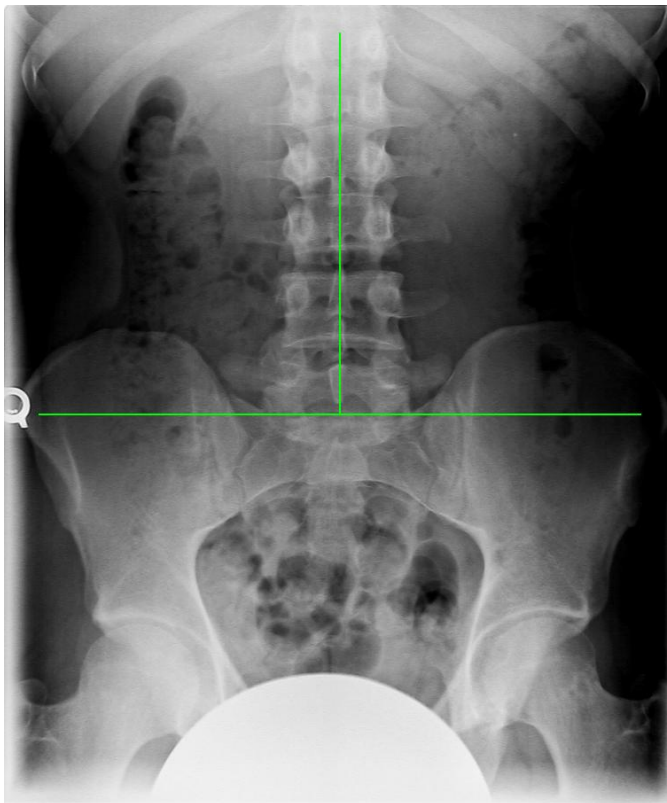
The green line represents the normal, healthy position for your low back.

No arthritis and healthy joint spaces are visualized.

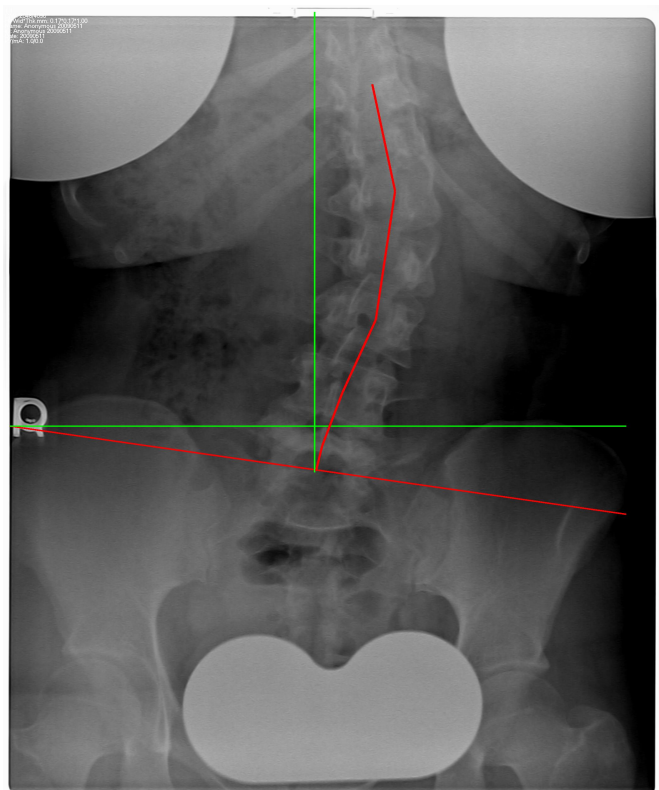
Your low back position from the front.

This green line represents the normal, healthy position for your low back.

This red line represents where your low back is currently positioned.



Right



Left Right

Left

Notes about your condition:

Your lumbar x-ray demonstrated that you have a scoliosis that consists of one major curvature. Your curve measured from vertebra T11 to vertebra L3 measured 42.9° (severe) using the "Cobb" method analysis and measured 20.7° (moderate) using the "Risser-Ferguson" method of analysis. These methods of analysis are what spine doctors use to measure the severity of a scoliosis.

You have a significant scoliosis which I believe will stabilize and possibly reduce using our rehab methods along with a Scolicare brace as we discussed.



X-RAY Report of Findings

Front View of Your Low Back (AP Modified Ferguson View)

The normal healthy position of a low back from the front.

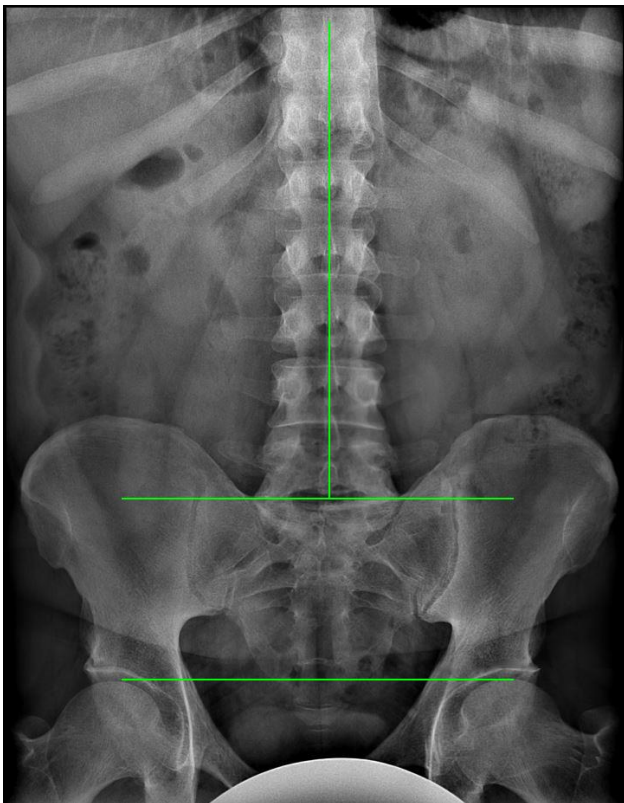
The green line represents the normal, healthy position for your low back.

No arthritis and healthy joint spaces are visualized.

Your low back position from the front.

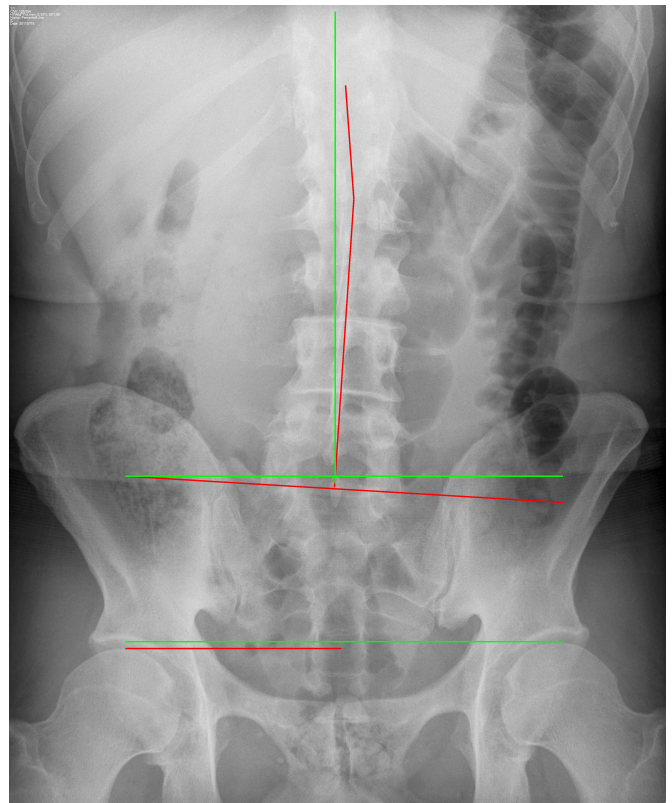
This green line represents the normal, healthy position for your low back.

This red line represents where your low back is currently positioned.



Right

Left



Right

Left

Notes about your condition:

The left side of your pelvis is low by 10.5mm relative to true horizontal. In addition, your leg bone height is short on the right side by 2.8mm.

Your low back is shifted 5.6mm to the left, you have a mid low back tilt angle of 8.4° and a lower tilt of 3.4°.

In this x-ray we had you standing on a 12mm ful lift under your left foot. This does balance your spine, thus we will need to have you wearing your lift and orthotic as we discussed.



X-RAY Report of Findings

References

- [1] Harrison DD, Janik TJ, Troyanovich SJ, Holland B. Comparisons of Lordotic Cervical Spine Curvatures to a Theoretical Ideal Model of the Static Sagittal Cervical Spine. *Spine* 1996;21(6):667-675.
- [2] Harrison DD, Harrison DE, Janik TJ, Cailliet R, Haas JW, Ferrantelli J, Holland B. Modeling of the Sagittal Cervical Spine as a Method to Discriminate Hypo-Lordosis: Results of Elliptical and Circular Modeling in 72 Asymptomatic Subjects, 52 Acute Neck Pain Subjects, and 70 Chronic Neck Pain Subjects. *Spine* 2004; 29(22):2485-2492.
- [3] Harrison DE, Janik TJ, Harrison DD, Cailliet R, Harmon S. Can the Thoracic Kyphosis be Modeled with a Simple Geometric Shape? The Results of Circular and Elliptical Modeling in 80 Asymptomatic Subjects. *J Spinal Disord Tech* 2002; 15(3): 213-220.
- [4] Harrison DD, Harrison DE, Janik TJ, Cailliet R, Haas JW. Do Alterations in Vertebral and Disc Dimensions Affect an Elliptical Model of the Thoracic Kyphosis? *Spine* 2003; 28(5): 463-469.
- [5] Janik TJ, Harrison DD, Cailliet R, Troyanovich SJ, Harrison DE. Can the Sagittal Lumbar Curvature be Closely Approximated by an Ellipse? *J Orthop Res* 1998; 16(6):766-70.
- [6] Harrison DD, Cailliet R, Janik TJ, Troyanovich SJ, Harrison DE, Holland B. Elliptical Modeling of the Sagittal Lumbar Lordosis and Segmental Rotation Angles as a Method to Discriminate Between Normal and Low Back Pain Subjects. *J Spinal Disord* 1998; 11(5): 430-439.
- [7] Harrison DE, Harrison DD, Cailliet R, Troyanovich SJ, Janik TJ. Cobb Method or Harrison Posterior Tangent Method: Which is Better for Lateral Cervical Analysis? *Spine* 2000; 25: 2072-78.
- [8] Harrison DE, Cailliet R, Harrison DD, Janik TJ, Holland B. Centroid, Cobb or Harrison Posterior Tangents: Which to Choose for Analysis of Thoracic Kyphosis? *Spine* 2001; 26(11): E227-E234.
- [9] Harrison DE, Harrison DD, Janik TJ, Harrison SO, Holland B. Determination of Lumbar Lordosis: Cobb Method, Centroidal Method, TRALL or Harrison Posterior Tangents? *Spine* 2001; 26(11): E236-E242.
- [10] Harrison DE, Holland B, Harrison DD, Janik TJ. Further Reliability Analysis of the Harrison Radiographic Line Drawing Methods: Crossed ICCs for Lateral Posterior Tangents and AP Modified Risser-Ferguson. *J Manipulative Physiol Ther* 2002; 25: 93-8.
- [11] Harrison DE, Harrison DD, Colloca CJ, Betz J, Janik TJ, Holland B. Repeatability of Posture Overtime, X-ray Positioning, and X-ray Line Drawing: An Analysis of Six Control Groups. *J Manipulative Physiol Ther* 2003; 26(2): 87-98.
- [12] Kauffman JM. Diagnostic Radiation: Are the risks exaggerated? *J Amer Phys Surg* 2003; 8(2): 54-55.
- [13] Cohen BL. Test of the linear-no threshold theory of radiation carcinogenesis for inhaled radon decay products. *Health Physics* 1995;68(2):157-174.
- [14] Cohen BL. The cancer risk from low level radiation: a review of recent evidence. *Med Sent* 2000;5:128-131.
- [15] Cohen BL. Cancer risk from low-level radiation. *AJR* 2002;179(5):1137-43.
- [16] Cohen BL. Catalog of risks extended and updated. *Health Physics* 1991; 61(3):317-335.
- [17] Walker JS. Permissible dose: A history of radiation protection in the 20th century. Berkeley, Calif: University of California Press, Berkeley, 2000.
- [18] Harrison DE, Harrison DD, Haas JW. Structural rehabilitation of the cervical spine. Evanston, WY: Harrison CBP? Seminars, Inc., 2002.
- [19] Harrison DE, Harrison DD, Haas JW, Betz J, Oakley PA. CBP? Structural rehabilitation of the lumbar spine. Evanston, WY: Harrison CBP? Seminars, Inc., 2005.
- [20] Regano LJ, Sutton RA. Radiation dose reduction in diagnostic X-ray procedures. *Phys Med Biol* 1992;37(9):1773-1788.
- [21] Luckey TD. Radiation Hormesis. Boca Raton: CRC Press, 1991;5:228-230.
- [22] Luckey TD. Nurture with ionizing radiation: a provocative hypothesis. *Nutrition Cancer* 1999; 34(1):1-11.
- [23] Sherwood T. 100 years' observation of risks from radiation for British male radiologists. *Lancet* 2001; 358:604.
- [24] Stokes IAF, Bevins TM, Lunn RA. Back surface curvature and measurement of lumbar spinal motion. *Spine* 1987;12:355-361.
- [25] Johnson GM. The correlation between surface measurement of head and neck posture and the anatomic position of the upper cervical vertebrae. *Spine* 1998;23:921-927.
- [26] Refshauge KM, Goodsell M, Lee M. The relationship between surface contour and vertebral body measures of upper spine curvature. *Spine* 1994;19:2180-2185.
- [27] Mosner EA, Bryan JM, Stull MA, Shippee R. A comparison of actual and apparent lumbar lordosis in black and white adult females. *Spine* 1989;14:310-331.
- [28] Committee to Assess Health Risks from Exposure to Low Levels of Ionizing Radiation. Health risks from exposure to low levels of ionizing radiation: BEIR VII Phase 2. National Research Council. Washington DC: National Academies Press, 2005.
- [29] Kant K, Chauhan RP, Sharma GS, Chakravarti SK. Hormesis in animals exposed to low-level ionizing radiation. *Inter J Low Rad* 2003; 1(1):76-87.
- [30] Feinendegen LE. Evidence for beneficial low level radiation effects and radiation hormesis. *Br J Radiol* 2005;78:3-7.
- [31] Parsons PA. Hormesis: an adaptive expectation with emphasis on ionizing radiation. *J Appl Tox* 2000;20:103-112.
- [32] Pollycove M. The issue of the decade: hormesis. *Eur J Nucl Med* 1995;22:399-401.
- [33] Pollycove M. Nonlinearity of radiation health effects. *Env Health Persp* 1998;106:363-368.
- [34] Luckey TD. Hormesis with Ionizing Radiation. CRC Press, Boca Raton, FL, 1980:
- [35] Cohen BL. Problems in the radon vs. lung cancer test of the linear no-threshold theory and a procedure for resolving them. *Health Phys* 1997;72:623-628.



X-RAY Report of Findings

References

- [36] Cohen BL. Updates and extensions to tests of the linear no-threshold theory. *Technology* 2000;7:657-672.
- [37] Frigerio NA, Eckerman KF, Stowe RS. Carcinogenic hazard from low-level, low-rate radiation, Part I. Rep.ANL/ES-26.Argonne Nat.Lab 1973.
- [38] Jagger J. Natural background radiation and cancer death rate in Rocky Mountain and Gulf Coast States. *Health Phys* 1998;75:428-434.
- [39] Kostyuchenko VA, Krestina L. Long-term irradiation effects in the population evacuated from the east-Urals radioactive trace area. *Sci Total Environ* 1994;142:119-125.
- [40] Matanoski, G. M. Health effect of low level radiation in shipyard workers: final report. Report no. DOE DE-AC02-79 EV10095. 1991. Washington, DC, US Dept of Energy.
- [41] Hickey RJ, Bowers EJ, Clelland RC. Radiation hormesis, public health, and public policy: a commentary. *Health Phys* 1983;44:207-219.
- [42] Tubiana M. The carcinogenic effect of low doses: the validity of the linear no-threshold relationship. *Int J Low Rad* 2003;1:1-33.
- [43] Cameron JR. Moderate dose rate ionizing radiation increases longevity. *Br J Radiol* 2005;78:11-13.
- [44] Cameron JR. Radiation increased the longevity of British radiologists. *Br J Radiol* 2002;75:637-640.
- [45] Cameron JR. Longevity is the most appropriate measure of health effects of radiation. *Radiol* 2003;229:14-15.
- [46] Cameron JR. Is radiation an essential trace energy? *Physics and Society* 2001;Oct:<http://www.aps.org/units/fps/newsletters/2001/october/a5oct01.html>
- [47] Parsons PA. Radiation hormesis: an ecological and energetic perspective. *Med Hypoth* 2000;57:277-279.
- [48] Luckey TD. Radiation hormesis in cancer mortality. *Chi Med J* 1994;107:627-630.

MEET THE DOCTORS

ADVANCED CHIROPRACTIC ASSOCIATES

PHONE: 727-848-2663

MEET DR. JOSEPH FERRANTELLI



Joseph R. Ferrantelli, D.C. graduated with honors from Florida State University in 1995 with a B.S. in Biological Sciences and earned his Doctor of Chiropractic (D.C.) degree from Life University School of Chiropractic, graduating Magna Cum Laude in March 1999. He has been serving the New Port Richey area for the past 5 years. Dr. Ferrantelli is a distinguished Fellow of Clinical Biomechanics of Posture® and a Chiropractic Biophysics® instructor for Chiropractic Biophysics® Technique. Dr. Ferrantelli was named the "2002 CBP® Chiropractic of the Year" Clinical Biomechanics of Posture® Annual Convention. In addition to normal practice, Dr. Ferrantelli teaches CBP® Chiropractic Technique throughout the U.S. and internationally. He is a contributing author for the rehabilitation textbook entitled, CBP® Structural Rehabilitation of the Cervical Spine as well as the soon to be released textbook, CBP® Structural Rehabilitation of the Lumbar Spine. Additionally, Dr. Ferrantelli has been published in the **JMPT** journal for an article focusing

on corrective treatment of chronic Whiplash Associated Disorders. Furthermore, he is a co-author on an original research paper published on normal spinal modeling in the world's most prestigious orthopedic medical journal, **Spine**. Currently, Dr. Ferrantelli has original research in press on postural assessment validity in another top orthopedic journal, the **European Spine Journal**. Dr. Ferrantelli is a regular contributing author for the American Journal of Clinical Chiropractic. Presently, Dr. Ferrantelli is collaborating on several original research studies pertaining to the study of motor vehicle whiplash injuries and their rehabilitative treatment as well as studying posture reliability and validity outcome assessment tools. Dr. Ferrantelli focuses his private practice on whiplash traumatology and has been trained in Auto Crash Reconstruction (LOSRI) through the Spine Research Institute of San Diego. Dr. Ferrantelli focuses on gentle family chiropractic care, Auto Accident injuries, and CBP® Structural Rehabilitation of the spine and posture. At this time, he is also the vice-president of the FCA's North Suncoast Chiropractic Society. Additionally, Dr. Ferrantelli runs one of the largest chiropractic technique websites (for CBP®) in the world, www.idealspine.com. Dr. Ferrantelli can be reached at 727-848-2663 or through his clinic website at www.normalspine.com.

MEET DR. CARA HACHT

Cara L. Hacht, D.C., L.M.T. graduated with her Doctor of Chiropractic (D.C.) in 1994 from the "Fountain Head of Chiropractic", Palmer College of Chiropractic in Davenport, IA. While at Palmer, she concurrently obtained her Bachelors of Science degree. Prior to her D.C. degree, Dr. Hacht graduated as a licensed massage therapist in 1989. Before becoming a Doctor of Chiropractic, Dr. Hacht worked as a licensed massage therapist for 5 years in the Pasco and Pinellas county. Consequently, when practicing as a chiropractor, Dr. Hacht uses a wide range of different Chiropractic and massage therapy techniques. In addition to gentle diversified chiropractic care, extremity adjusting and the Palmer Package, she also focuses on the Chiropractic Biophysics® (CBP®) technique. While in practice, Dr. Hacht has participated as an active member of the Florida Chiropractic Association and currently the president of the North Suncoast Chiropractic Society, which is a local chapter of the Florida Chiropractic Association. She has been practicing in Pasco, Pinellas and Hillsborough county since 1995. She opened her practice with Dr. Ferrantelli in February of 2001. Dr. Hacht can be reached at Advanced Chiropractic Associates, or through their website www.normalspine.com.

Society, which is a local chapter of the Florida Chiropractic Association. She has been practicing in Pasco, Pinellas and Hillsborough county since 1995. She opened her practice with Dr. Ferrantelli in February of 2001. Dr. Hacht can be reached at Advanced Chiropractic Associates, or through their website www.normalspine.com.

8406 MASSACHUSETTS AVE, SUITE A2, NEW PORT RICHEY, FL 34653

PHONE: 727-848-2663 ONLINE: WWW.NORMALSPINE.COM

Helping a family in pain with specific, structurally-based chiropractic care

Advanced Chiropractic Associates

Joe Ferrantelli, DC

Visit Advanced Chiropractic Associates on the Web at www.normalspine.com.

“When I was young, I went through a series of car accidents,” remembers Sue Skaggs. “In a two-year period I was hit four times, and hit hard.

“It was like I had a sign on me that said, *Hit me.*”

Sue developed severe headaches that nothing could alleviate, and they continued to make her life miserable through her thirties and into her forties.

“The doctors told me I had nerve damage, but there wasn’t much they could do about it,” she explains. “They would give me anti-inflammatory medication and pain pills, but I’m not a person to take medication – I really don’t like to, unless I have to.

“It was very debilitating,” she adds. “If I tried to pick up my grandson, it would trigger a headache immediately.”

Sue had some success with traditional chiropractic care, and when she moved from Long Island to Florida, she consulted a different chiropractor, Joe Ferrantelli, DC. Affectionately known to his patients as “Dr. Joe,” Dr. Ferrantelli provides specific structural-based chiropractic treatment in a comfortable, caring environment.

Chiropractic Biophysics

“When she came in to see me, Sue had already undergone traditional chiropractic care,” confirms Dr. Ferrantelli, “but nothing resolved her problem long term. For quite some time, she still wished to continue with traditional methods as they worked for ‘patching up’ her pain and headaches, but I suggested that she try a more permanent approach through specific structurally-based rehabilitation.”

Dr. Ferrantelli helps patients with stubborn pain problems like Sue’s heal correctly with Chiropractic Biophysics (CBP) rehabilitation methods. “To use an analogy, I explain that a CBP chiropractor is like the ‘orthodontist’ within the chiropractic profession,” explains Dr. Ferrantelli.

“The best way to restore Sue to proper function, while simultaneously relieving her pain and headaches, was with CBP, which is structural-based rehabilitative care,” states Dr. Ferrantelli.

Dr. Ferrantelli focuses his corrective regimens with *Mirror Image* postural exercises and a specialized form of postural/spinal traction to accomplish rehabilitation of chronic spinal pain, headaches, and other common ailments like numbness, tingling, and sciatica.

“Many patients are surprised that they need traction as part of their treatment, as they only associate traction with being stretched vertically,” says Dr. Ferrantelli. “However, the traction I

use for certain patients is much different and highly specific. Properly applied, *Mirror Image* traction is not simple traction, but is specific to realign the spine towards a more normal, healthier position.

“We began Sue’s treatment with traditional chiropractic adjustments and therapy. Then we promoted her into full spinal rehabilitation. In her case, she had a loss of normal neck curve. The type of traction used was able to apply gentle, yet prolonged, cervical extension, restoring her neck curve, thereby relieving her pain and chronic headaches.” This protocol was augmented by specific chiropractic adjustments for postural correction along with aggressive postural-based corrective exercises.

use for certain patients is much different and highly specific. Properly applied, *Mirror Image* traction is not simple traction, but is specific to realign the spine towards a more normal, healthier position.

“He’s awesome”

“I started to see relief almost immediately,” reports Sue. “Now I just go in once a month for what I call a *tune-up*, and I’m absolutely fine.”

In fact, Sue’s treatment was so successful, she recommended Dr. Ferrantelli to her daughter and son-in-law, Val and Mike Harris.

“I had a loss of curvature in my neck,” explains Val, “and I constantly had headaches. Dr. Joe started me with traction, too, and today I no longer have headaches. That was several years ago.”

Even after being involved in multiple car accidents like her mother, Val has found Dr. Ferrantelli’s treatment to be effective.

“I had two accidents in 2001 and one in 2005,” says Val. “I never actually stopped treatments with Dr. Joe, though, so it’s worked out perfectly.”

And when Val’s husband Mike had a pain problem, both mother and daughter were able to direct him to Dr. Ferrantelli.

“I was having a lot of back pain,” recalls Mike, who boxes recreationally. “It hurt to box for a long period of time.”

The pain affected his activities of daily living as well.

“Just standing at the bed folding clothes, or washing dishes, my back would start bothering me,” says Mike. “I could only do those things for short periods of time.”

After receiving treatment from Dr. Ferrantelli, Mike says, “The results are great. Between work, boxing, and home life, it’s made a huge improvement in my being able to do things for longer periods of time.”

“I’m back to normal boxing activities, too. In fact, I just did four rounds of sparring today, with no pain, no problems.”

This family sings Dr. Ferrantelli’s praises.

“Dr. Joe is very committed to his patients,” says Sue, “and he’ll work with you in whatever way he possibly can to make things happen, because he’s trying to make you better.”

“He’s a great person,” adds Val. “Dr. Joe is more than just a doctor, where you go in and get treated and leave. You can tell that he truly cares about you and he wants to help you.”

“And everybody in his practice is like that,” she continues, “very helpful and catering to the patients’ needs.”

“It’s definitely a positive experience going there,” agrees Sue. “We need a lot more like him. He’s awesome.”

PHOTO: Michael J. Salmo



KEEPING IT IN THE FAMILY.
Sue, Mike, and Val (left to right) are all doing well again thanks to Dr. Ferrantelli (far right).



Joseph Ferrantelli, DC, graduated with honors from Florida State University in 1995 with a bachelor of science in biological sciences and earned his doctor of chiropractic degree from Life University School of Chiropractic, graduating magna cum laude, in March 1999. Dr. Ferrantelli is a distinguished fellow of clinical biomechanics of posture

and certified instructor for CBP Seminars. Dr. Ferrantelli was named CBP Chiropractor of the Year by CBP Seminars in 2002. Additionally, he has coauthored manuscripts published in top scientific orthopedic and chiropractic journals such as *Spine*, *European Spine Journal*, and *Journal of Manipulative and Physiological Therapeutics*. Dr. Ferrantelli is also a contributing author for the *Practicing Chiropractors' Committee on Radiological Protocols* to be published in 2007. In addition, he is primary investigating researcher in the International Chiropractors Association's up and coming “Best Practices” clinical practice guidelines for the chiropractic profession. Dr. Ferrantelli focuses on gentle family chiropractic care, auto accident injuries, and CBP structural rehabilitation of the spine and posture. Dr. Ferrantelli is also president of the FCA's North Suncoast Chiropractic Society.

Your spine is in great hands

For more information on Advanced Chiropractic Associates' spinal workshops, or to schedule a consultation, call the office at (727) 848-2663. Advanced Chiropractic is located at 8406 Massachusetts Ave., Suite A2, in New Port Richey.