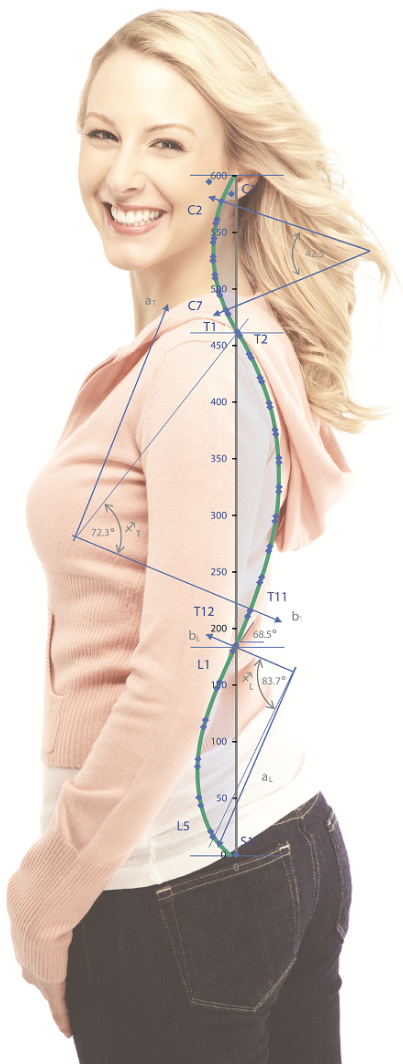




# MODERN CHIROPRACTIC CENTER

## Radiographic Instability Report



Prepared for: Bad Spine  
Patient #: SpineBad2013629000  
Insurance #:  
Gender: Male  
Date of Birth: 8/7/1954  
Address:

Evaluation Date: 6/29/2013  
Date X-Ray Taken: 6/29/2013

Prepared by:  
Modern Chiropractic  
Someplace Drive  
Somewhere Cityville, Florida  
34653



## Radiographic Instability Report

## Lateral Cervical Flexion/Extension

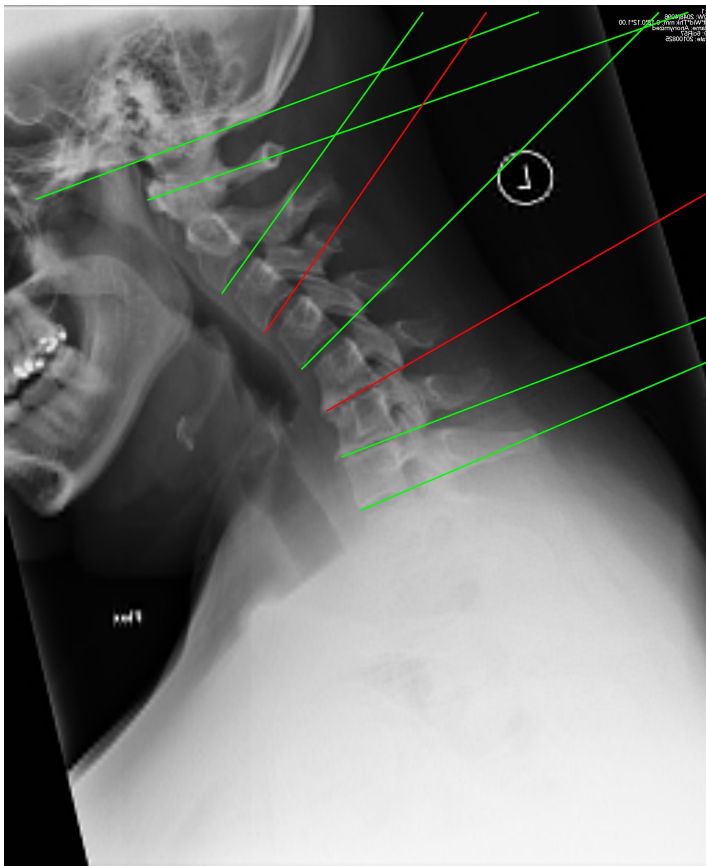
**Name: Bad Spine**  
**Date of Birth: 8/7/1954**

**X-Ray was obtained: 6/29/2013**

**Date of Digitization: 6/29/2013**

Mr. Bad Spine's x-rays were analyzed utilizing the PostureRay® computerized X-ray digitizing system with impressions interpreted by Dr. Joe Ferrantelli. X-Ray digitization for spinal biomechanics has been shown to be valid when compared to standard hand drawn methods. The patient's findings were then compared to established normals at each level and then globally. The X-Ray mensuration method used in analyzing this patient have been studied for reliability and validity and these results are as follows:

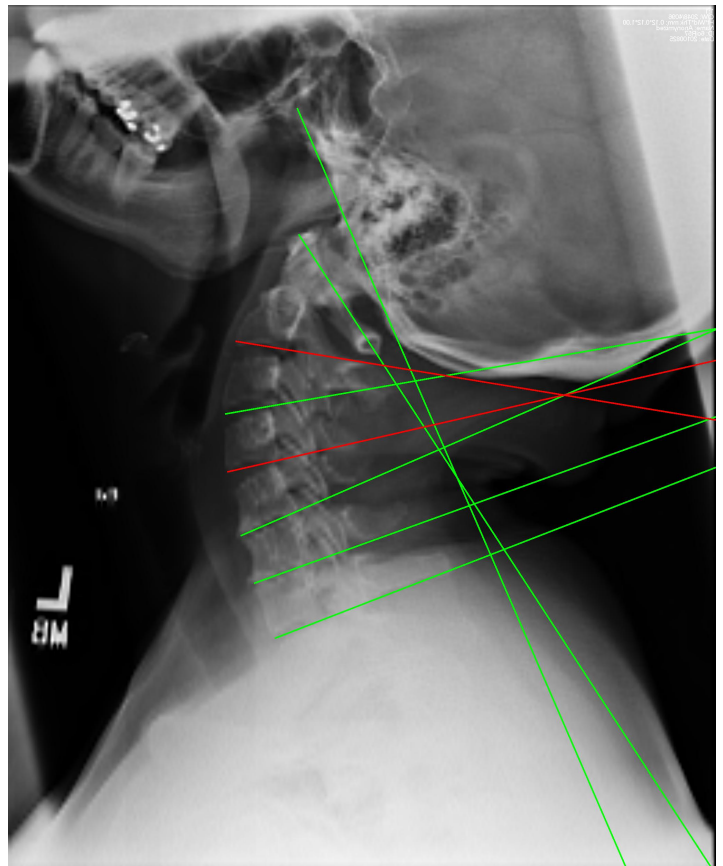
### Flexion



**Anterior**

**Posterior**

### Extension



**Anterior**

**Posterior**

The green line represents vertebrae motion below the ratable threshold for alteration of motion segment integrity.

The red line represents vertebral motion above the ratable threshold indicating alteration of motion segment integrity.



## Radiographic Instability Report

## Lateral Cervical Flexion/Extension

### Endplate Analysis for Flexion/Extension positions

Segment	Normal Values	Flexion Values	Extension Values	Normal Values	Flexion Transl.	Extension Transl.
C2-C3	n/a	-0.9°	<b>-19.2°</b>	< 3.5 mm	-1.2 mm	-2.9 mm
C3-C4	< 11° *	<b>10.4°</b>	-3.0°	< 3.5 mm	0.2 mm	-2.7 mm
C4-C5	< 11° *	15.2°	<b>-10.6°</b>	< 3.5 mm	0.4 mm	-1.6 mm
C5-C6	< 11° *	<b>8.9°</b>	3.6°	< 3.5 mm	0.3 mm	-0.1 mm
C6-C7	< 11° *	-2.2°	-1.4°	< 3.5 mm	0.0 mm	0.4 mm

\* The value refers to the difference between this and the previous or subsequent line. The absolute larger of the two is highlighted.

Values in Red Exceed Established Normal

Direction of measured displacements are indicated using the right-hand Cartesian coordinate system method in biomechanics. Consequently a "-" negative sign preceding a measured value indicates posterior translation for linear movements; and a "-" preceding angular measurements indicate relative segmental or global extension rotational movement.

Upper Cervical Measurements - Flexion	Normal Values	Patient Values	Clinical Significance
Powers Ratio	0.9 to 1	0.9	WNL
Basilar Impression (McRae's method)	n/a	WNL	WNL
Atlanto-Dental Interspace	≤ 3 mm	1.5 mm	WNL
Spinal Canal Diameter	> 13 mm	24.9 mm	WNL

WNL = Within Normal Levels

Upper Cervical Measurements - Extension	Normal Values	Patient Values	Clinical Significance
Powers Ratio	0.9 to 1	1.1	Anterior Atlantooccipital dislocation may exist
Basilar Impression (McRae's method)	n/a	WNL	WNL
Atlanto-Dental Interspace	≤ 3 mm	0.7 mm	WNL
Spinal Canal Diameter	> 13 mm	27.3 mm	WNL

WNL = Within Normal Levels

Upper Cervical Measurements - Flexion + Extension	Normal Values	Patient Values	Clinical Significance
C0-C1 Instability	< 25°	Not Digitized	Not Digitized
C1-C2 Instability	< 20°	12.3°	WNL

WNL = Within Normal Levels



## Radiographic Instability Report

## Lateral Cervical Flexion/Extension

### Penning Analysis Total Average Angular Excursion

Segmental Angular Excursion	Normal Values (Penning*)	Normal Values (Dvorak**)	Normal Values (Wu***)	Patient Values
C2-C3	12.0°	12.0°	13.5°	14.9°
C3-C4	18.0°	17.2°	17.3°	18.6°
C4-C5	20.0°	21.1°	22.6°	20.1°
C5-C6	20.0°	22.6°	19.1°	10.2°
C6-C7	15.0°	21.4°	18.0°	2.4°

\* see Reference 6

\*\* see Reference 5

\*\*\* see Reference 7

Values in Red Exceed Established Normal

Direction of measured displacements are indicated using the right-hand Cartesian coordinate system method in biomechanics. Consequently a "-" negative sign preceding a measured value indicates posterior translation for linear movements; and a "-" preceding angular measurements indicate relative segmental or global extension rotational movement.

### Impressions and Assessment

The Endplate Analysis for this area of the spine (constructing tangential lines from inferior vertebrae C2-7) has been noted in the scientific literature for objective analysis of vertebral segmental alignment in the neutral, flexion, and extension views.<sup>[5]</sup> This method was adopted by the AMA Guides to the Evaluation of Permanent Impairment as a method to discriminate an alteration of motion segment integrity (AOMSI) suggestive of an unstable spine<sup>[1,5]</sup>. AOMSI has been defined as abnormal motion equal to or exceeding 11° of angular movement and/or 3.5mm of translational slippage (break in "George's Line") relative to adjacent vertebral segments.<sup>[1,5]</sup> Such excessive movement is indicative of ligamentous sub-failure as well as possible disc damage. Consequently, a patient may be rateable for a permanent injury upon reaching maximal medical improvement should these alterations of spinal biomechanics persist.<sup>[1]</sup> Regarding the magnitude of translational slippage (break in "George's Line") other researchers have argued that 3.5mm is simply too large of a displacement of magnitude seldom observed in clinical practice<sup>[4]</sup> and that clinical relevance should be noted at motion ranging from lower thresholds of 1.0-3.0mm indicating subluxation.<sup>[3]</sup> Others have noted, "To adopt 3.5mm of translation as the minimum criterion for anterior subluxation is to leave the majority of mild to moderate instability unclassified."<sup>[2]</sup>

In the flexion position, there are some ratable levels for angular instability but no ratable levels for translational instability. Increase in angulation is noted at C3-C4 of 10.4° compared to C2-C3 of -0.9° which is > 11° difference at 11.3°, C5-C6 of 8.9° compared to C6-C7 of -2.2° which is > 11° difference at 11.1° which may be of clinical significance. Threshold for angular excursion should not exceed 11° more than adjacent levels. Also noted in this global flexed position is subluxation (break in "George's Line") of C2-C3 with -1.2 mm. Absolute threshold cutoff is defined by the AMA Guides as translation slippage (break in "George's Line") of greater than 3.5mm. In this position, there are no ratable levels of abnormal translational slippage instability (break in "George's Line").



## Radiographic Instability Report

## Lateral Cervical Flexion/Extension

In the extension position, there are some ratable levels for angular instability but no ratable levels for translational instability. Increase in angulation is noted at C2-C3 of  $-19.2^\circ$  compared to C3-C4 of  $-3.0^\circ$  which is  $> 11^\circ$  difference at  $16.2^\circ$ , C4-C5 of  $-10.6^\circ$  compared to C5-C6 of  $3.6^\circ$  which is  $> 11^\circ$  difference at  $14.2^\circ$  which may be of clinical significance. Threshold for angular excursion should not exceed  $11^\circ$  more than adjacent levels. Also noted in this global extended position is subluxation (break in "George's Line") of C2-C3 with  $-2.9$  mm, C3-C4 with  $-2.7$  mm, C4-C5 with  $-1.6$  mm. Absolute threshold cutoff is defined by the AMA Guides as translation slippage (break in "George's Line") of greater than  $3.5$  mm. In this position, there are no ratable levels of abnormal translational slippage instability (break in "George's Line").

Using the Penning system of analysis<sup>[6]</sup>, Mr. Bad Spine's cervical spine was analyzed using computerized method and total motion at each segmental level was assessed. Penning's Analysis for cervical spine stability has been shown to be one of the most valid methods for assessing total range of motion from flexion to extension.<sup>[5]</sup> Mr. Bad Spine was found to have excessive motion exceeding normal ranges found in the literature. These were C2-C3 of  $14.9^\circ$ , C3-C4 of  $18.6^\circ$ , C4-C5 of  $20.1^\circ$ . Consequently, ligamentous instability and loss of motion segment integrity exists at these levels when assessing for total movement from the flexion to extension position. At C2-C3 of  $14.9^\circ$ , C3-C4 of  $18.6^\circ$ , the total motion exceeded that of normal ranges found by Dvorak<sup>[5]</sup> and Wu<sup>[7]</sup>.

**Flexion View Impressions:** Very limited global ROM is noted with associated spinal coupling. No acute bony abnormalities or osseous disease.

**Extension View Impressions:** Very limited global ROM is noted with associated spinal coupling most noted mid to lower cervical spine. I suspect delayed instability will appear once more normal global ROM is achieved.

**According to the above biomechanical assessment, there are findings of alteration of motion segment integrity (AOMSI) at the following levels: C2-C3, C3-C4, C4-C5 and C5-C6. Consequently, this patient may be ratable for a permanent injury upon reaching maximal medical improvement.**

## References

- [1] Guides to the Evaluation of Permanent Impairment, Fifth Edition. American Medical Association, 2000.
- [2] Foreman SM CAC. Whiplash Injuries: The Cervical Acceleration / Deceleration Syndrome. 3rd ed. Lippincott Williams and Wilkins, 2002:52-53.
- [3] Green JD, Harle TS, Harris JH, Jr. Anterior subluxation of the cervical spine: hyperflexion sprain. AJNR Am.J.Neuroradiol. 1981;2:243-50.
- [4] Scher AT. Anterior cervical subluxation: an unstable position. AJR Am.J.Roentgenol. 1979;133:275-80.
- [5] Dvorak J, Froehlich D, Penning L et al. Functional radiographic diagnosis of the cervical spine: flexion/extension. Spine 1988;13:748-55.
- [6] Penning L. Normal Movements of the Cervical Spine. Am J Roentgenol 1978;317-26.
- [7] Wu SK, Kuo LC, Lan HC et al. The quantitative measurements of the intervertebral angulation and translation during cervical flexion and extension. Eur.Spine J 2007;16:1435-44.
- [8] Guides to the Evaluation of Permanent Impairment, Sixth Edition. American Medical Association, 2007.





## Radiographic Instability Report

## Lateral Lumbar Flexion/Extension

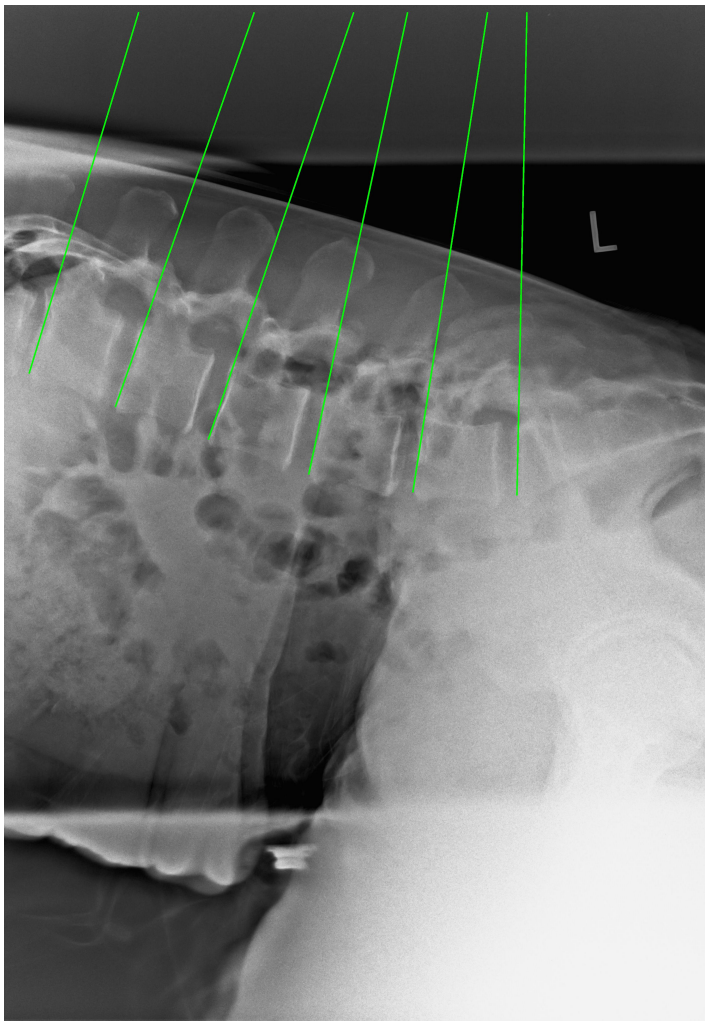
**Name: Bad Spine**  
**Date of Birth: 8/7/1954**

**X-Ray was obtained: 6/29/2013**

**Date of Digitization: 6/29/2013**

Mr. Bad Spine's x-rays were analyzed utilizing the PostureRay® computerized X-ray digitizing system with impressions interpreted by Dr. Joe Ferrantelli. X-Ray digitization for spinal biomechanics has been shown to be valid when compared to standard hand drawn methods. The patient's findings were then compared to established normals at each level and then globally. The X-Ray mensuration method used in analyzing this patient have been studied for reliability and validity and these results are as follows:

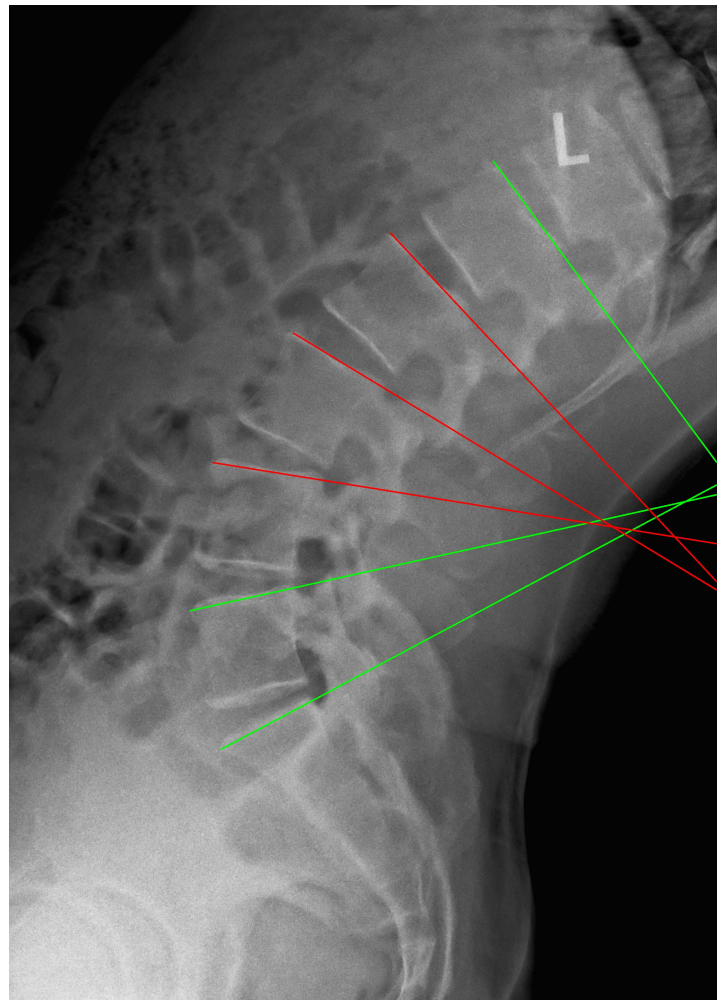
### Flexion



**Anterior**

**Posterior**

### Extension



**Anterior**

**Posterior**

The green line represents vertebrae motion below the ratable threshold for alteration of motion segment integrity.

The red line represents vertebral motion above the ratable threshold indicating alteration of motion segment integrity.



## Radiographic Instability Report

## Lateral Lumbar Flexion/Extension

### Endplate Analysis for Flexion/Extension positions

Segment	Normal Values	Flexion Values	Extension Values	Normal Values	Flexion Transl.	Extension Transl.
L1-L2	< 15°	2.5°	-6.5°	< 4.5 mm	0.1 mm	-2.6 mm
L2-L3	< 15°	-0.6°	<b>-15.6°</b>	< 4.5 mm	-0.5 mm	-3.2 mm
L3-L4	< 15°	-6.7°	<b>-22.1°</b>	< 4.5 mm	-1.5 mm	-3.6 mm
L4-L5	< 20°	-3.2°	<b>-21.5°</b>	< 4.5 mm	1.8 mm	-0.7 mm
L5-S1	< 25°	-7.6°	-15.6°	< 4.5 mm	1.1 mm	-1.3 mm

Values in Red Exceed Established Normal

Direction of measured displacements are indicated using the right-hand Cartesian coordinate system method in biomechanics. Consequently a "-" negative sign preceding a measured value indicates posterior translation for linear movements; and a "-" preceding angular measurements indicate relative segmental or global extension rotational movement.

### Impressions and Assessment

Lumbar spinal assessment utilizing end-plate mensuration techniques is well established for defining an alteration of motion segment integrity. According to the AMA Guides, a "Motion Segment" is defined as two vertebrae that are at adjacent levels, and includes the adjacent disk and facet joints and ligamentous structures between the vertebrae.<sup>[1]</sup> In this analysis above, measurements were obtained both in the flexion and extension positions of the lumbar spine and the difference is calculated from flexion to extension. According to the AMA Guides, "A diagnosis of Alteration of Motion Segment Integrity (AOMSI) in the lumbosacral spine by angular motion measurements requires greater than a 15° at L1-2, L2-3 and L3-4; greater than 20° at L4-5, or greater than 25° at L5/S1 when compared to adjacent level angular motion." Further, the AMA guides delineates that any translational movement greater than 4.5mm of slippage anterior or posterior relative to adjacent level also qualifies as a loss of structural integrity, i.e. an alteration of motion segment integrity.<sup>[2]</sup>

In the flexion position, there are no ratable levels for angular instability nor for translational instability. Threshold for angular instability should not exceed the values previously stated of 15 degrees at L1-2, L2-3 and L3-4; 20 degrees at L4-5, or 25 degrees at L5/S1. Also noted in this global flexed position is subluxation (break in "George's Line") of L3-L4 with -1.5 mm, L4-L5 with 1.8 mm, L5-S1 with 1.1 mm. Absolute threshold cutoff is defined by the AMA Guides as translation slippage (break in "George's Line") of greater than 4.5mm. In this position, there are no ratable levels of abnormal translational slippage instability (break in "George's Line").

In the extension position, there are some ratable levels for angular instability but no ratable levels for translational instability. Increase in angulation is noted at L2-L3 of -15.6°, L3-L4 of -22.1°, L4-L5 of -21.5° which may be of clinical significance. Threshold for angular excursion should not exceed the values previously stated of 15 degrees at L1-2, L2-3 and L3-4; 20 degrees at L4-5, or 25 degrees at L5/S1. Also noted in this global extended position is subluxation (break in "George's Line") of L1-L2 with -2.6 mm, L2-L3 with -3.2 mm, L3-L4 with -3.6 mm, L5-S1 with -1.3 mm. Absolute threshold cutoff is defined by the AMA Guides as translation slippage (break in "George's Line") of greater than 4.5mm. In this position, there are no ratable levels of abnormal translational slippage instability (break in "George's Line").



## Radiographic Instability Report

## Lateral Lumbar Flexion/Extension

**Flexion View Impressions:** No bony abnormalities noted. There is mild anterolisthesis of L4 on L5 as noted and measured.

**Extension View Impressions:** Laxity is noted and measured in extension secondary to the persistent hyperlordosis.

According to the above biomechanical assessment, there are findings of alteration of motion segment integrity (AOMSI) at the following levels: L2-L3, L3-L4 and L4-L5. Consequently, this patient may be ratable for a permanent injury upon reaching maximal medical improvement.

### References

- [1] Guides to the Evaluation of Permanent Impairment, Fifth Edition. American Medical Association, 2000.
- [2] Guides to the Evaluation of Permanent Impairment, Sixth Edition. American Medical Association, 2007.